

Aus der Radiologischen UniversitätsKlinik Tübingen
Abteilung Diagnostische und Interventionelle
Neuroradiologie

Motor and language resting state functional
magnetic resonance imaging in brain tumor patients

Dissertation
submitted for a doctoral degree in
human sciences

at the
Faculty of Medicine
of the Eberhard Karls Universität
Tübingen

submitted by
Liouta, Evangelia
2019

Dean: Professor Dr. I. B. Autenrieth

First reviewer: Professor Dr. S. Bisdas

Second reviewer: Professor Dr. K. Scheffler

Date of oral examination: 19.06.2019

Dedication

To my beloved ones,

Vivianna Lianou & Leonardos-George Lianos

Table of contents

1. INTRODUCTION..... 9

1.1 Brain tumors..... 9

1.2 Brain tumor and neurological-neuropsychological deficits..... 10

1.3 Brain tumors and surgery..... 11

1.4 Brain tumor surgery and functional Magnetic Resonance Imaging..... 12

1.5 Resting state functional Magnetic Resonance Imaging..... 13

1.6 Resting state functional Magnetic Resonance Imaging analysis types... 15

1.7 Resting state functional Magnetic Resonance and brain disorders..... 15

1.8 Resting state functional Magnetic Resonance and brain tumors..... 17

1.8.1 *Resting state functional Magnetic Resonance and motor function.....* 17

1.8.2 *Resting state functional Magnetic Resonance and language function...* 18

1.9 Aim of the present study..... 18

2. METHODS..... 20

2.1 Participants..... 20

2.2 Clinical assessment..... 23

2.2.1 *Motor.....* 23

2.2.2 *Language.....* 25

2.3 RS-fMRI acquisition..... 26

2.4 RS-fMRI analysis..... 26

2.4.1 *Pre-processing.....* 26

2.4.2 *Post-processing.....* 27

2.5 Statistical analysis..... 29

3. RESULTS..... 31

3.1	Clinical data.....	31
3.1.1	<i>Motor</i>	31
3.1.2	<i>Language</i>	31
3.2	RS-fMRI data.....	32
3.2.1	<i>Patients</i>	32
3.2.2	<i>Healthy subjects</i>	38
3.3	RS-fMRI and clinical data.....	44
3.3.1	<i>Motor</i>	44
3.3.2	<i>Language</i>	45
3.4	RS-fMRI in patients and healthy controls: comparison.....	47
3.4.1	<i>Motor</i>	47
3.4.2	<i>Language</i>	50
4.	DISCUSSION	51
4.1	RS-fMRI in brain tumors.....	51
4.2	RS-fMRI and motor function.....	51
4.3	RS-fMRI and language function.....	55
4.4	RS-fMRI and tumor histology.....	58
4.5	RS-fMRI in patients and healthy controls: comparison.....	61
4.5.1	<i>Motor</i>	61
4.5.2	<i>Language</i>	63
4.6	Methodological considerations.....	64
4.7	Conclusions.....	66
5.	SUMMARY	67
5.1	German summary.....	69

6. BIBLIOGRAPHY	71
7. DECLARATION OF CONTRIBUTIONS.....	78
8. PUBLICATIONS	79
9. AKNOWLEDGMENTS	80
Author's curriculum Vitae.....	81

Abbreviations

ANOVA Analysis of Variance

BA Broadman Area

BOLD Blood Oxygenation Level-Dependent

CNS Central Nervous System

COWAT Controlled Oral Word Association Test

DCS Direct Cortical Stimulation

DMN Default Mode Network

ECS Electrical Cortical Stimulation

EPI echo-planar imaging

FA Flip Angle

fMRI functional Magnetic Resonance Imaging

FOV Field of View

FWHM Full Width at Half Maximum

GBM Glioblastoma Multiforme

GRE Gradient Echo

HGG High Grade Glioma

IC Independent Component

ICA Independent Component Analysis

IES Intraoperative Electrical Stimulation

IFG Inferior Frontal Gyrus

LGG Low Grade Glioma

MEG Magnetoencephalography

MPRAGE Magnetization-Prepared Rapid Gradient Echo Sequence

PET Positron Emission Tomography

ROIs Regions of Interest

RS-fMRI Resting State functional Magnetic Resonance Imaging

RSN Resting State Network

SD Standard Deviation

SMA Supplementary Motor Area

SPM Statistical Parametric Mapping

TE Echo Time

TMS Transcranial magnetic stimulation

TR Repetition time

WHO World Health Organization

1. INTRODUCTION

In the present dissertation, the validity of a new advanced neuroimaging technique, the resting state functional Magnetic Resonance Imaging (RS-fMRI), will be tested as a potential pre-operative brain function mapping tool, that may allow in the future neurosurgeons to employ it when traditional and well established methods fail to map eloquent areas, a procedure that is essential when planning operating brain tumors. In order to appreciate the aim of the present research, it is crucial for the reader firstly to understand the nature of the brain tumors, the effect they may have on human behavior/neurological status, the respective impact of the surgery, and the role that the modern neuroimaging techniques play in the functional outcomes of a brain tumor surgery. For this reason, a brief overview of the aforementioned issues will be given in the first part of the monograph.

1.1 Brain tumors

According to World Health Organization (WHO) 2016 (Louis et al., 2016) there are more than 160 different types of the Central Nervous System (CNS) primary tumors. Primary brain tumors are categorized in accordance to their histological grade into benign and malignant ones.

One of the most common primary (not metastatic) brain tumor is meningioma; meningiomas consist 20-30% of all brain tumors and they are presented more often in females than males (Bondy et al., 1996). Meningiomas are benign tumors (Grade I) in their majority whereas a small number of them can be atypical (Grade II) or even malignant (Grade III). Although meningiomas are considered extra-parenchymal lesions, as they arise from arachnoid cells that cover brain parenchyma, they can however affect brain functions depending on their location and size (Liouta et al., 2015) and depending on their location they may consist a real challenge for a neurosurgeon with regards to their removal (Saraf et al., 2011).

Gliomas on the other hand are the most prevalent type of non-benign brain tumors consisting a little less than half of all primary brain tumors. Depending on the cell type they arise from, the two most common subtypes of gliomas are astrocytomas (the most

common) and oligodendrogliomas. Astrocytomas grow from glial cells that their main functional role is to nourish nerve cells. They are subdivided into grades I to IV with grades III and IV tumors to grow faster and having greater malignancy than the lower grades. Beginning with the lowest in grading, Grade I astrocytomas usually are found in children and young adults and more rarely in older. They are not as invasive as the rest of grades and typically present a good prognosis. Grade II astrocytomas are presented in young adults rather than in elderly and they are considered low-grade too; however they can mutate over time and become high-grade tumors (III & IV). Grade III astrocytomas - known also as anaplastic astrocytomas- have a relatively poor prognosis. Grade IV astrocytomas or glioblastoma multiforme (GBM) have very poor prognosis - the worst of all brain tumors. GBMs consist the majority of gliomas and the can be either *de novo*, being grade IV from the beginning) or secondary (beginning as II or III grade and changing in the course-time of the disease). Oligodendrogliomas the second type of gliomas arise from oligodendrocytes, cells responsible for insulating nerve fibres. Oligodendrogliomas are subdivided into low grade II and high grade III, with the last ones to be known also as anaplastic oligodendrogliomas (see Jovčevska et al, 2013 for review).

1.2 Brain tumor and neurological-neuropsychological deficits

Depending on three key parameters location, size and nature of neoplasm namely, brain tumors may affect patients' neurological and neuropsychological-cognitive functions such as motor, language, vision, memory etc. There are two main mechanisms that can induce such a dysfunction. The first one is the compression of normal brain tissue caused directly by the tumor or indirectly by the edema that may accompanies the tumor; the second one, that is usually seen in parenchymal glial tumors, is the invasion of tumors directly into functional brain areas or indirectly by disconnecting brain structures that cooperate for a specific function (Klein et al, 2012).

In gliomas, the most common primary intra-parenchymal neoplastic entity, the frequency of neuropsychological deficits found in patients is not rare; Apart from seizures, which is the main symptom at presentation, brain glioma patients may present with focal neurologic signs and cognitive impairment. With regards to Low Grade

Gliomas (LGG), modern bibliography supports that, although seizure is the most common symptom with up to 80% of patients to present it (Pignatti et al., 2002), cognitive deficits also can be seen in up to 70% of patients when formal neuropsychological assessment takes place. Cognitive deficits in High-Grade Glioma (HGG) are seen even more frequently, in up to 80% of patients (Habets et al., 2014) but they may be initially overshadowed by pronounced neurological deficits.

Apart from gliomas, extra-axial tumors, such as meningiomas, may cause neurocognitive dysfunction in patients that harbor those (Liouta et al., 2015). In this study authors report that patients with a typical meningioma (grade I) perform significantly worse in several neurocognitive domains than healthy controls, with the patients with skull base meningioma to show more disturbances in memory than patients with convexity ones and patients with anteriorly located meningiomas to show more deficits in executive functions than patients with meningiomas located posteriorly. Verbal deficits also were more pronounced in the left hemisphere than in the right hemisphere and patients with a large tumor showed more severe neurocognitive impairment than those with a small tumor, highlighting thus the prognostic value of the location and the size that a tumor may have on neuro-psycho-logical functioning.

1.3 Brain tumors and surgery

The standard-care treatment of primary brain tumors remains until today the surgical removal. However, brain tumors surgery, especially the one for intra-parenchymal neoplasms, can be challenging for the neurosurgeon; apart from the tumor itself, surgery treatment may also cause neurological and cognitive dysfunction. Although resection of a tumor can result in functional improvement in cases where cognitive deficits caused by a reactive edema, neurological and cognitive status may deteriorate due to healthy tissue damage evoked by surgery. This is why aim of the modern neurooncological surgery is to maximize the extent of tumor resection, offering thus a better prognosis to patients, with a parallel minimization of postoperative neurological-neuropsychological deficits, offering thus a good quality of life. This holds particularly for gliomas the most common malignant brain tumor; as glioma patients cannot be cured, one of the most important outcomes of a surgery, apart from the oncological ones per se, is the preservation of neurological -cognitive functions. Since there is growing evidence that

maximal resection prolongs survival for both LGG and HGG (Hervey-Jumper & Berger, 2014; Marko et al. 2014), functional imaging techniques, that will be discussed in the next section, have been proven to play a critical role in detecting a preoperative map of the main functional brain regions e.g. motor and language areas, providing thus surgeons with valuable information for their planning of a tumor approach (Fiscaro et al., 2016), and allowing them subsequently to extent their resections with the maximal functional safety.

1.4 Brain tumor surgery and functional Magnetic Resonance Imaging

Preoperative localization of eloquent cortex is considered necessary in order to optimize brain tumor resection and minimize in parallel post-operative neurological and neuropsychological dysfunction. In preoperative setting, several techniques have been employed over the last years in order to invasively lateralize (Wada test- intracarotid amobarbital procedure) and non-invasively localize brain functions such as the Positron Emission Tomography (PET), the Magnetoencephalography (MEG) and the Transcranial Magnetic Stimulation (TMS). However, among all the non-invasive preoperative mapping techniques, task-based functional Magnetic Resonance Imaging (fMRI) has been the standard one to localize sensorimotor and language functions. fMRI has been validated by comparing its results with the findings from the “gold standard” mapping of intraoperative electrical stimulation (IES) for both language and motor functions (see Giussani et al., 2010 for review).

fMRI is a widely used technique that measures indirectly brain function by depicting changes associated with blood flow, when a subject performs a task, and which in turn are linked to neuronal activation. When a brain area is processing information, during subjects' engagement in specific tasks e.g. upper-lower limbs and tongue movement, language generation and comprehension, and listening to music, blood flow to that area also increases. So, fMRI theoretically it is based upon the so-called blood oxygenation level-dependent (BOLD) effect. According to this effect when an brain part is in use neuronal cells show an increment in oxygen consumption, with a parallel increment of the local perfusion (Glover, 2011). Although its wide use in clinical settings, task-based fMRI is accompanied by some weaknesses that affect its effectiveness in practice. The major drawback is that, due to that this technique demands patient's active

involvement, a satisfactory task-related performance may not be obtained by some patients such as those with motor (paralysis, paresis, apraxia etc.) or mental/cognitive (attentional, mnemonic, linguistic etc.) deficits due to a lesion and/ or medications.

1.5 Resting state functional Magnetic Resonance Imaging

A technological advance that has been developed over the last years and potentially can overcome some of the task-based fMRI mapping flows, is the discovery that spontaneous brain BOLD fluctuations are synchronized, making thus functional networks, even if a subject is theoretically in rest - non participating in any cognitive processing (Fox & Raichle 2007). As we mentioned previously, RS-fMRI may be conducted on subjects unable to successfully perform tasks within the MRI suite, as patients presented with cognitive decline (including aphasic disorders) or motor weakness. Another benefit of RS-fMRI is the ability to depict a number of functional networks at the same time, useful in cases where a clinician needs mapping information from multiple functional networks such as in preoperative planning of a tumor in vicinity of both language and motor areas; in these cases scanning time can be dramatically reduced in comparison to task-based fMRI (Bookheimer, 2007). In addition, task-based fMRI paradigms can vary across institutions as they depend to a certain degree on the administration guidance, making therefore its external validation vulnerable (Bookheimer, 2007); RS-fMRI on the other hand is less limited by the above issue, as tasks and their putative variability in design are absent in this technique.

According to the theoretical background of RS-fMRI, it is assumed that low frequency fluctuations ($<0.1\text{Hz}$) that occur spontaneously in the BOLD-signal in brain during rest are synchronized in several functionally connected areas (networks). How important are those fluctuations in terms of functionality was first stated by Bharat Biswal (Biswal et al, 1995). In this study, subjects performed a traditional motor task-based fMRI and an fMRI without an explicit task (resting state). The researchers selected an area in the left somatosensory cortex based on the results from motor task fMRI, and then they sought to investigate the correlation of that selected area with all other brain regions. What they discovered was that there was a robust correlation between the left somatosensory cortex and the homologous region of the right somatosensory cortex (Biswal, et al., 1995).

Since then, RS-fMRI has been used as in order to study different functional regions and a number of networks have been recognized by several studies: perhaps the resting state network (RSN) that has been studied mostly in the literature is the Default Mode Network (DMN). DMN discovered by Greicius and colleagues in 2003 conducting rs-fMRI analysis in data from healthy subjects. What the authors noted was that consistent brain areas were active when volunteers were at rest but when they engaged to a cognitive task those areas were less active (Greicius et al., 2003). Those areas corresponded mainly to the anatomical regions of bilateral precuneus, bilateral posterior, anterior and middle cingulate gyrus, left and right angular gyrus and bilateral middle frontal gyrus. In contrast to DMN that is more active when a subject is at rest, several other RSNs, which are composed by areas known to be involved in tasks, have been identified.

The following RSNs have been named accordingly due to their anatomical properties as well as their putative functional significance: the sensorimotor network that includes mainly areas in proximity with central sulcus, namely the bilateral precentral gyrus- primary motor cortex, the bilateral postcentral gyrus- primary somatosensory cortex (Brodmann areas 4 and 3 respectively), as well as secondary planning motor regions such as the supplementary motor area (SMA) that corresponds to Brodman area 6. The auditory network that is comprised by left and right superior temporal gyrus; the visual network occupies the occipital cortex and consists of bilateral lingual gyrus, bilateral calcarine gyrus and bilateral cuneus as well as associated vision areas such as left and right inferior parietal lobule and left and right inferior temporal gyrus(Allen et al., 2011).

RSNs that participate in attentional processing have been also identified throughout ventral and dorsal regions of parietal and frontal lobes bilaterally (Fox et al., 2006). In regards with language function, a network that involves Broca's and Wernicke's epicenters (Tomasi et al., 2012) but also frontal networks (Allen et al., 2011) that include left and right inferior frontal gyrus (Brodman areas 44 & 45) have been reported in the literature. Finally, a basal ganglia network consisting of left and right putamen has been identified. (Allen et al., 2011).

1.6 Resting state functional Magnetic Resonance Imaging analysis types

RS-fMRI data may be analysed using different techniques among which seed based method and Independent Component Analysis (ICA) are the two most known methods, being employed by the majority of the current literature. As we mentioned in the previous section the first ever method used was the seed based analysis, which has been employed in a number of studies since Biswal's study. In this type of analysis, brain Regions of Interest (ROIs) are selected according to the study subject, and the average BOLD time course of voxels within these ROIs are correlated with each other as well as the time courses of all other voxels in the brain. Typically, a threshold is determined to identify voxels significantly correlated with the region of interest.

ICA (Beckmann et al., 2005) on the other hand is a statistical technique that maximizes statistical independence between its components. ICA is applied to RS-fMRI data in order to spatially distinguish RSNs. ICA, in contrast to seed-based analysis, does not necessitate a priori selection of ROIs; in brain tumors research, where RS-fMRI may be used as a tool for eloquent areas' mapping, seed-based analysis may not be the most methodologically appropriate technique to use; that is because -plasticity induced-relocation of cerebral functions may take place in benign or low-grade gliomas (Duffau,2014) making thus difficult to be confident about the correspondence of anatomical seeds to respective functions. When it comes to language, coupling of anatomy and function may be further difficult using seed-based methods, due to the anatomical inconsistency of expressive and receptive language regions that brain tumor patients may present (Tate et al., 2014). Therefore, it would be assumed that ICA derived RSNs would delineate underlying cerebral functions more reliably than seed-based technique when they are placed near lesions producing mass effect; this is why we employed ICA in the present study rather than seed-based analysis (see section: aim of the present study).

1.7 Resting state functional Magnetic Resonance and brain disorders

A significant amount of RS-fMRI research has focused on dementia disorders over the last decade. More specifically, studies have shown the potential role of RS-fMRI in

identifying Alzheimer's disease patients. Using RS-fMRI graph analysis, Supekar and colleagues (2008) showed that cluster coefficients in the hippocampus (a well-known atrophic brain area in Alzheimer's patients) were significantly reduced in patients when compared to healthy controls and this biomarker could separate Alzheimer's disease patients from healthy with a good sensitivity (72%) and specificity (78%) (Supekar et al., 2008). DMN, extracted either by ICA or seed based methods, has been also suggested as a potential biomarker for distinguishing healthy subjects from Alzheimer's patients with 97% accuracy of (Koch et al., 2012). Even more interestingly, relevant studies have presented promising results on the potential utility of RS-fMRI in separating patients with Mild Cognitive Impairment –a clinical stage that usually precedes Alzheimer's disease- from normal controls (Chen et al., 2011) but also in distinguishing within-dementia groups e.g. Alzheimer's disease, frontotemporal dementia and Lewy Body Dementia patients (Takamura & Hanakawa, 2017).

Apart from neurodegenerative disorders, RS-fMRI has been also used as a potential diagnostic tool different neurological-psychiatric diseases; consciousness disorders such as Persistent Vegetative State and Minimally Consciousness State have been studied by RS-fMRI with the results to suggest that abnormalities in DMN connectivity is related to the level of consciousness (Vanhaudenhuyse et al., 2010). In addition, the most common neuropsychiatric diseases such as depression and bipolar disorder (Takamura & Hanakawa, 2017), schizophrenia (Yu et al. 2012), Attention Deficit Hyperactivity Disorder (Posner et al., 2014) and autism (Anderson et al., 2011) have been explored by RS-fMRI with the results to identify abnormalities in different RSNs linked to each one of the aforementioned disorders.

In the neuro-surgical field apart from tumors, which will be discussed throughout the dissertation, epilepsy is one more clinical entity that has been studied by RS-fMRI. Here, the potential utility of functional connectivity has been applied in the context of presurgical identification of epileptogenic zone needed to be removed for treating seizures. Results are promising, as increased functional connectivity in specific brain areas seem to overlap with epileptogenic foci, as confirmed by the traditional -so far- tool for epileptogenic foci's identification, the encephalography (see Lee et al., 2013 for review).

1.8 Resting state functional Magnetic Resonance and brain tumors

Over the last years several studies have focused on RS-fMRI networks and tumors- especially gliomas- and have highlighted the clinical utility that RS-fMRI techniques may have in the future of neurosurgical setting. Based on the aim of the papers, current literature is comprised by two main categories: Studies focusing on the RS-fMRI networks' changes that may have been caused by a tumor and studies that aim to localize eloquent areas in brain tumors. In the former category, studies have shown decreased long distance functional connectivity in RS-fMRI networks caused by gliomas (Niu et al., 2014; Vassal et al., 2017), distinct changes in RS-fMRI networks according to tumor grading (Harris et al., 2014; Esposito et al., 2012; Zhang et al., 2016), the potential role of RS-fMRI technique for measuring tumors' infiltration (Chow et al., 2016) and the potential role of RS-fMRI networks' properties as a prognostic factor (Tuovinen et al., 2016). In the latter category research has focused on the validity of RS-fMRI in mapping eloquent areas such as sensorimotor and language areas by comparing resting state with task-based fMRI and positive sites from intraoperative electrical stimulation mapping (for an excellent review see Ghinda et al,2018).

1.8.1 Resting state functional Magnetic Resonance and motor function

Concerning motor function, previous studies have aimed to validate RS-fMRI as a mapping tool in the preoperative setting by comparing resting state with motor task-based fMRI, with encouraging findings (Zhang et al., 2009; Liu et al., 2009; Rosazza et al., 2014; Qiu et al., 2014) and with more recent (Schneider et al., 2016) evidence to support a modest anatomical overlapping of the two types of analysis for specific areas of motor cortex (face, hand and foot homunculus sub-regions). In the former four studies mentioned above, not only motor function but also iatrogenic kinetic dysfunction, was correlated to RS-fMRI activations exhibiting a good spatial agreement in a small clinical sample nevertheless. In those studies, motor dysfunction was evoked by Electrical Current Stimulation (ECS) with the use of electrode strips placed over the pre-central and post-central gyrus intraoperatively. Preoperative motor deficits were also reported by Otten and colleagues (2012) to have a strong correlation with motor RSNs' connectivity between SMA and primary motor areas (Otten et al., 2012).

1.8.2 Resting state functional Magnetic Resonance and language function

Similar to motor function, most of RS-fMRI studies for language function have aimed to demonstrate a spatial comparison between resting state techniques and task-based fMRI paradigms, with results to suggest that RS-fMRI maybe a useful tool in mapping networks of linguistic function in patients with brain tumors (Wang et al., 2013; Sair et al., 2016; Branco et al., 2016). The similarity of spatial properties between the two techniques however do not provide us with information about the RS-fMRI functional validity and does not gives us insight into RS-fMRI correlation with language clinical status that can be derived by clinical examination. So far, there is scarce evidence that addresses this issue by correlating behavioural clinical data- elicited by awake craniotomy mapping for speech in tumor patients- with pre-surgical RS-fMRI. Accordingly, Cochereau et al. (2016) claimed that, in general, spatial properties of language areas as extracted by RS-fMRI show great similarity with the ones evidenced by intraoperative stimulation in patients with a glioma type of tumor; however, in individual analysis authors noticed a RS-fMRI variability in identifying accurately language areas, suggesting that more research needed in order to use RS-fMRI as a reliable mapping tool in clinical neurosurgical setting (Cochereau et al., 2016).

1.9 Aim of the present study

Use of RS-fMRI in clinical tumor neurosurgical setting prerequisites research that will evidence a strong correlation between anatomical properties of the RS-fMRI networks and corresponding brain functions that underlie these structural areas in patients with brain masses. As we mentioned earlier proof of correlational relationship between RS-fMRI network activations and neurological/neuropsychological (dys)functions in the preoperative setting of brain tumor surgery is very limited so far. In addition, considering that pre-surgical functional mapping with MRI inform us about brain's functionality before any surgical treatment, we considered that investigating the correlational relationship between pre-surgical RS-fMRI connectivity and patients' pre-surgical/baseline functional status would largely contribute in the RS-fMRI validity as a clinical tool; our effort is in line with directions of previous studies for future research (Lang et al., 2014). Taken all the above into account, this study aims is to provide

evidence for the validity of the functional motor and language networks of ICA derived RS-fMRI, by investigating their relationship with pre-surgical motor and language functions' integrity, as derived by neurological and neuropsychological assessment, in patients planned to undergo brain tumor resection.

2. METHODS

2.1 Participants

Eighty five right-handed patients harboring brain tumors [mean age= 47 years, standard deviation (SD)=15.1 years, range= 18-78 years, 48 female and 37 male patients], candidates for tumor resection, were recruited in a prospective fashion from the Department of Neurosurgery, Medical School of Athens. All the patients underwent preoperatively RS-fMRI and clinical assessments. There were three exclusion criteria 1) patients with tumor relapse, 2) patients with additional neurological diseases and 3) patients taking medication known to affect cognitive and motor behaviors. Depending on the mass location, our sample was divided into two groups (in cases that tumor was placed near language and motor regions, those patients participated in both groups,). As a result we conducted 94 RS-fMRI individual analyses: Patients having neoplasms over or in the vicinity of motor strip (motor group, n=59, mean age±SD 47.0±15.3 years, male/female= 31/28) were tested with motor clinical assessment and clinical data were correlated with the motor RS-fMRI network; patients having neoplasms over or in the proximity to inferior frontal gyrus (IFG) of the left hemisphere (language group, n=35, mean age±SD 45.2±14.5 years, male/female ratio 15/20)] were tested with clinical assessment of language and clinical data were correlated with language network RS-fMRI data. Individual demographics and tumor histology of patients are provided in Table 1. In addition, twenty seven age-matched healthy subjects were recruited and their RS-fMRI analyses of motor and language networks served as an additional control group. All subjects gave their informed consent before the start of the study; the present research was conducted in accordance to the Helsinki Declaration, and received approval by the local Committee for Ethics.

Table 1. Patients' demographics and histological results of patients' tumors

Code	Gender	Age	Tumor histology
101	2	40	Grade IV Glioma-Glioblastoma Multiforme
102	2	68	Grade I Meningioma
103	2	60	Grade IV Glioma-Glioblastoma Multiforme

104	2	34	Grade I Meningioma
105	2	76	Grade I Meningioma
106	1	58	Grade IV Glioma-Glioblastoma Multiforme
107	1	34	Grade I Cavernous Hemangioma
108	1	60	Grade IV Glioma-Glioblastoma Multiforme
109	2	60	Grade II Glioma-Astrocytoma
110	2	27	Grade II Glioma -Astrocytoma
111	1	62	Grade IV Glioma-Glioblastoma Multiforme
112	2	72	Grade IV Glioma- Glioblastoma Multiforme
113	1	30	Grade II Glioma- Astrocytoma
114	1	58	Grade IV Glioma-Glioblastoma Multiforme
115	2	55	Grade I Meningioma
116	2	34	Grade I Meningioma
117	2	43	Grade I Meningioma
118	2	60	Grade I Meningioma
119	2	59	Grade I Meningioma
120	2	29	Grade I Meningioma
121	1	25	Grade II Glioma- Astrocytoma
122	2	56	Grade IV Glioma-Glioblastoma Multiforme
123	2	46	Grade II Glioma- Oligodendroglioma
124	1	77	Grade I Meningioma
125	2	59	Grade IV Glioma-Glioblastoma Multiforme
126	2	73	Grade IV Glioma- Glioblastoma Multiforme
127	2	32	Grade II Glioma- Astrocytoma
128	1	44	Grade IV Glioma- Glioblastoma Multiforme
129	1	69	Grade IV Glioma-Glioblastoma Multiforme
130	1	54	Grade II Glioma- Oligodendroglioma
131	2	18	Grade III Glioma- Anaplastic Oligodendroglioma
132	2	63	Grade IV Glioma- Glioblastoma Multiforme

133	1	43	Grade II Glioma-Astrocytoma
134	1	36	Grade II Glioma- Astrocytoma
135	1	74	Grade IV Glioma- Glioblastoma Multiforme
136	2	54	Grade I Meningioma
137	2	23	Grade I Meningioma
138	2	46	Grade IV Glioma- Glioblastoma Multiforme
139	2	55	Grade IV Glioma- Glioblastoma Multiforme
140	1	60	Grade IV Glioma- Glioblastoma Multiforme
141	1	78	Grade IV Glioma- Glioblastoma Multiforme
142	1	57	Grade IV Glioma- Glioblastoma Multiforme
143	2	29	Grade III Glioma- Anaplastic Oligodendroglioma
144	2	62	Grade IV Glioma- Glioblastoma Multiforme
145	2	51	Grade I Meningioma
146	1	68	Grade IV Glioma- Glioblastoma Multiforme
147	1	45	Grade III Glioma- Anaplastic Oligodendroglioma
148	1	36	Grade II Neurocytoma
149	2	27	Grade II Glioma- Astrocytoma
150	2	47	Grade IV Glioma- Glioblastoma Multiforme
151	1	29	Grade II Glioma- Oligodendroglioma
152	2	22	Grade IV Glioma- Glioblastoma Multiforme
153	2	74	Grade I Meningioma
154	1	65	Grade I Meningioma
155	1	51	Grade IV Glioma- Glioblastoma Multiforme
156	2	53	Grade IV Glioma- Glioblastoma Multiforme
157	2	30	Grade I Hemangioma
158	1	44	Grade IV Glioma- Glioblastoma Multiforme
159	1	48	Grade IV Glioma- Glioblastoma Multiforme
160	2	73	Grade IV Glioma- Glioblastoma Multiforme
161	2	41	Grade IV Glioma- Glioblastoma Multiforme

162	1	57	Grade IV 4 Glioma- Glioblastoma Multiforme
163	1	57	Grade IV Glioma- Glioblastoma Multiforme
164	1	47	Grade IV Glioma- Glioblastoma Multiforme
165	2	70	Grade II Ependymoma
166	1	43	Grade II Glioma- Astrocytoma
167	1	42	Grade IV Glioma- Glioblastoma Multiforme
168	2	39	Grade II Glioma- Astrocytoma
169	2	53	Grade I Cavernous Hemangioma
170	1	36	Grade III Glioma- Anaplastic Astrocytoma
171	2	45	Grade II Glioma- Oligodendroglioma
172	2	44	Grade II Glioma (radiologically presumed-no biopsy)
173	2	30	Grade IV Glioma- Glioblastoma Multiforme
174	2	51	Grade IV Glioma- Glioblastoma Multiforme
175	1	49	Grade IV Glioma- Glioblastoma Multiforme
176	2	42	Grade II Glioma- Oligodendroglioma
177	2	53	Grade IV Glioma- Glioblastoma Multiforme
178	2	50	Grade IV Glioma- Glioblastoma Multiforme
179	2	45	Grade III Glioma- Anaplastic astocytoma
180	2	32	Grade II Glioma- Astrocytoma
181	1	48	Grade II Glioma- Astrocytoma
182	1	24	Grade II Glioma- Oligodendroglioma
183	1	50	Grade III Glioma- Anaplastic Oligodendroglioma
184	1	38	Grade I Cavernous hemangioma
185	1	21	Grade II Glioma - Ganglioglioma

2.2 Clinical assessment

2.2.1 Motor

Clinical examination for paresis-muscle weakness was employed in order to assess motor function grossly and finger tapping task (Reitan & Wolfson, 1985) was utilized in order to assess fine motor function that usually is overlooked in a typical neurological examination. Briefly, finger tapping test is a neuropsychological tool, which demand from the individuals to tap their index finger on a lever, as quickly as they can, for a trial lasting 10 seconds. A device that counts the tapings is placed next to the lever and the examiner records the device's counting (figure 1). The 10- second trial is repeated for 5 times with brief time intervals or 10 times in cases that count difference among the trials exceeds the five taps. At the beginning of the test subjects receive a practice session, to make sure that they comprehend the instructions. At the end, the examiner calculates the mean number of tapings and this number consists subject's performance score. Subsequently, the whole procedure is conducted with the non-dominant hand- the left one in our study. Finger tapping is an easy to administrate test and the entire procedure lasts around 10 minutes.




Figure 1. Picture showing finger tapping test performed by an individuals with his hand palm placed down and his index finger to press the lever that is attached to the counting device (picture taken from <https://www.barrowneuro.org/education/grand-rounds-publications-and-media/barrow-quarterly/volume-13-no-4-1997/finger-tapping-brain-dysfunction-qualitative-quantitative-study/> by Prigatano GP and Hoffmann B (1997).

2.2.2 Language

Language function was assessed for its expressive component by administering the Boston Cookie theft (Goodglass et al., 2001) - a picture description task during which subjects are instructed to describe what is happening in the scene presented in the picture (figure 2) and any produced paraphasias-language errors are collected by the examiner. In parallel the Controlled Oral Word Association Test (COWAT) was employed for assessing fine linguistic function in patients presented with no motor-expressive aphasia. COWAT assess verbal fluency by measuring patients' ability to produce words beginning with a specific letter-phonemic subset- or the number of words that share a common category –semantic subset (Kosmidis et al., 2004). For the purpose of our study only phonemic subtest was conducted. During a 1-minute trial, patients were instructed to produce, as fast as they could, words starting with a designated letter (3 trials in total -A,X,S letters). The whole examination lasted around 5–6 minutes.




Figure 2. Cookie theft picture description test. From *the Boston Diagnostic aphasia Examination*. Goodglass H, Kaplan E & Barresi B, 2001.

2.3 RS-fMRI acquisition

Prior to RS-fMRI acquisition patients were instructed to abstain from any cognitive processing, being relaxed and having their eyes closed. RS-fMRI was collected by a 1.5 Tesla scanner (Siemens Symphony-Vision, Siemens Medical Solutions, Germany) with a standard head coil. In order to improve the fMRI acquisition, RS-fMRI was conducted in thirty four healthy subjects, employing several parameters [repetition time (TR) 2,000 msec / 3,000 msec; echo time (TE) = 50 msec / 40 msec; 300 / 250 / 223 dynamics with gradient echo (GRE) echo-planar imaging (EPI) employing axial orientation and including areas from of 4th ventricle roof to the vertex. We finally came to a halt with the parameters: 223 multi-slice T2*-weighted images/ GRE EPI-sequence axial oriented including regions from 4th ventricle roof to the vertex / 21 slices; T= 2,000 msec; TE= 50 msec; matrix size= 64 x 64 x 64; voxel size= 4 x 4 x 4 mm³; field of view (FOV) was 56 x 256 mm²; flip angle (FA) = 90°. The first three volumes were removed in order to refrain from any saturation effects in T1. In addition a high-resolution isotropic T1 transverse sequence [T1-weighted/ 3D magnetization-prepared rapid gradient echo sequence (MPRAGE)] was obtained as an anatomical reference for each participant (Liouta et al. 2018).

2.4 RS-fMRI analysis

2.4.1 Pre-processing

Methods of pre- and post-processing analyses were developed and conducted in the Department of Neuroradiology, University Hospital of Tübingen, Tübingen, Germany. Statistical Parametric Mapping (SPM8) software package (<http://www.fil.ion.ucl.ac.uk>) operated by Matlab (The MathWorks Inc., Natick, MA, USA) was employed for conducting RS-fMRI analysis pre-processing. Images were re-orientated manually for correction prior beginning with the pre-processing analysis. Pre-processing analysis comprised of five main steps: spatial realignment, a step for motor correction within a subject's session; co-registration of each subject's anatomical and functional images was the second step; after we co-registered the data we proceeded with segmentation of T1 image in grey matter, white matter and cerebrospinal fluid; segmentation was

followed by normalization of T1 into a standard space, the standard template in Montreal Neurological Institute. The last step we applied was smoothing: RS-fMRI data were smoothed, in order to increase signal to noise ratio, by applying a 10 mm Gaussian kernel full width at half maximum (FWHM) (Liouta et al., 2018).

2.4.2 Post-processing

After pre-processing, ICA method post-processing applied to the data by employing the Group ICA Of fMRI Toolbox -GIFT (<http://icatb.sourceforge.net>, version 1.3b) software operated by Matlab. Pre-processed data disintegrated into seventy five independent components (ICs) according to their spatial correlation in each subject (Allen et al., 2011). Time courses and spatial maps were produced for every IC. To identify the ICs that correspond to motor and frontal-language networks we employed a method that is incorporated in the GIFT toolbox and that matches spatial templates. According to this technique ICs are extracted through comparisons of the spatial maps of our data with spatial templates produced by Allen et al., 2011. The ICs of our data that presented the highest spatial regression coefficient to the corresponding templates produced by Allen et al., 2011, were chosen (see figure 5 for a paradigm of spatial regression map). Therefore, the IC correlated spatially to IC No. 20 frontal (see figure 3) and to IC No. 7 sensorimotor (see figure 4) networks (Allen et al., 2011) were selected. After selecting the network in interest we depicted the voxel that showed the maximum t-value and respective z-scores were utilized in order to delineate signal intensity. According to Allen and colleagues' study the core anatomical areas of the maximum BOLD-signal are the following (Allen et al., 2011): bilateral primary motor cortex-precentral gyrus (covering hand area) for IC No 7 and left IFG for IC No 20 (BA44, 45) (Liouta et al., 2018)

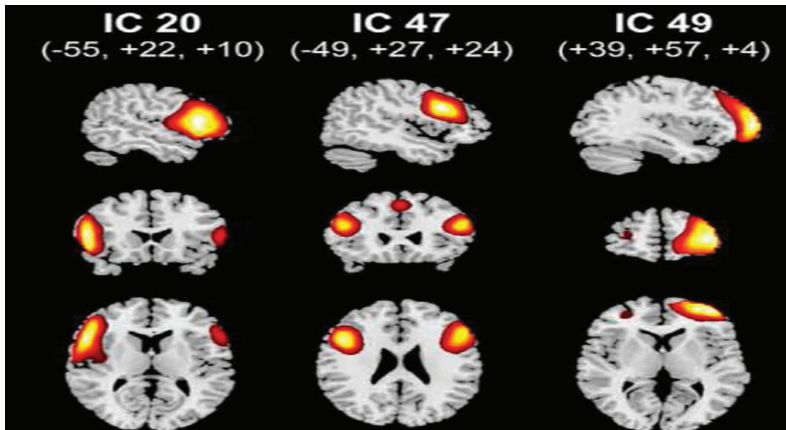


Figure 3. The three main frontal independent components (IC) extracted by Independent Component Analysis resting analysis according to Allen et al., 2001. For the purpose of our study we have chosen the IC 20 that corresponds anatomically to the left inferior frontal gyrus-Broadman areas 44, 45. (Picture taken from Allen EA, Erhardt EB, Damaraju E, Gruner W, Segall JM, Silva RF, et al. A Baseline for the Multivariate Comparison of Resting-State Networks. *Frontiers in Systems Neuroscience*. 2011;5:2. doi:10.3389/fnsys.2011.00002.)

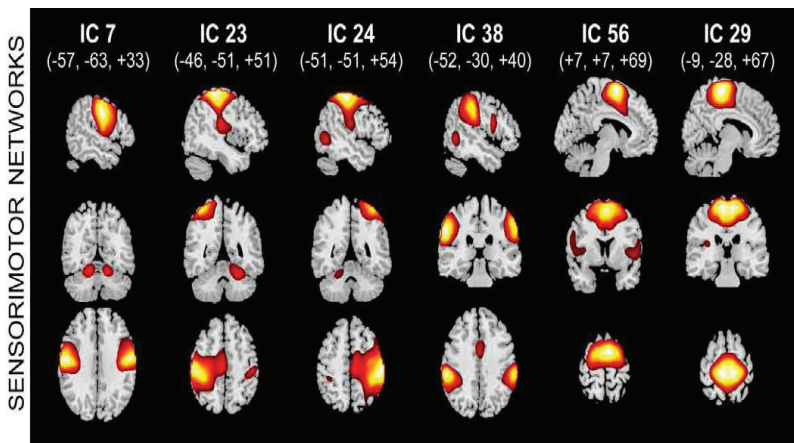


Figure 4. The six main sensorimotor independent components (IC) extracted by Independent Component Analysis resting analysis according to Allen et al., 2001. For the purpose of our study we have chosen the IC 7 that corresponds anatomically to the precentral gyrus bilaterally. (Picture taken from Allen EA, Erhardt EB, Damaraju E, Gruner W, Segall JM, Silva RF, et al. A Baseline for the Multivariate Comparison of

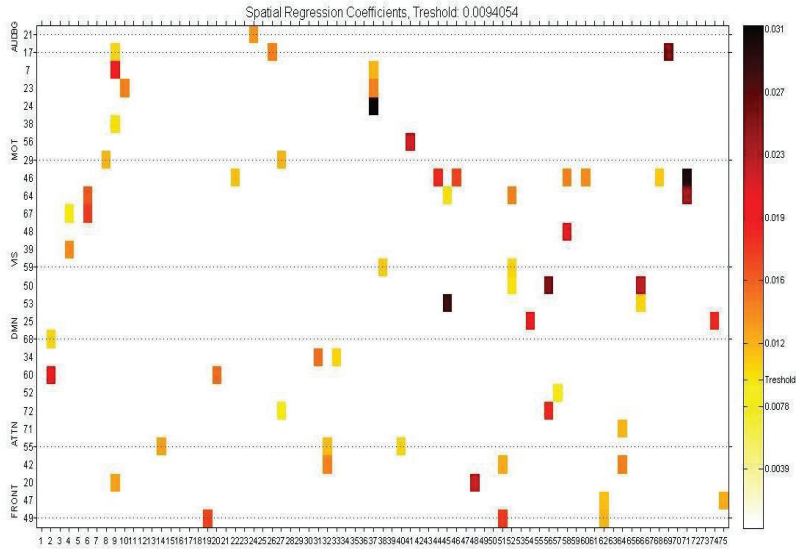


Figure 5. Spatial regression map generated by the GIFT tool box ICA analysis. Y-axis (left side) numbers represent Independent Component (IC) templates of Allen’s et al. study (2011); X-axis numbers represent ICs generated from our analysis for a subject data; Y-axis (right side) spatial regression coefficients between Allen’s study IC templates and our ICs.

2.5 Statistical analysis

SPSS software package was employed for analyzing the data of the present study (IBM SPSS statistics v.22 for Windows, SPSS Inc.). Our data met normality assumptions, in accordance to Shapiro-Wilk normality test. Clinical data for motor group: Finger tapping performance was used as a continuous variable and we run parametric Pearson’s correlations between finger tapping scores and IC7 motor network z-scores in patients presented with no paresis; in patients with muscle weakness parametric 2-sample independent t-test was employed in order to compare ipsilesional and intact-

contralesional IC7 motor network z-scores. Parametric 2-sample independent t-test was in addition used for comparison between paretics' IC7 ipsilesional motor network z-scores and non-paretics' IC7 ipsilesional motor network z-scores. Clinical data for language group: Phonemic verbal fluency performance was treated as continuous variable and parametric Pearson's correlations for language IC20 network z-scores and phonemic verbal fluency scores conducted for the group of non-aphasic patients. In addition, parametric 2-sample independent t-test was used for comparing ipsilesional IC20 language network z-scores between aphasic and non-aphasic patients.

Independent t-tests were also conducted between normal and patients in order to investigate putative differences in their RS-fMRI motor and language networks' activations. Independent t-tests, one way analysis of variance (ANOVA) and correlation analyses were conducted in order to investigate demographics and clinical characteristics' effects on BOLD signal activations of RS-fMRI networks. Cut-off p-value was set at <0.05 (Liouta et al., 2018).

3. RESULTS

3.1 Clinical data

3.1.1 Motor

With regards to motor group, seven patients exhibited at admission contralesional paresis and fifty two patients presented with no muscle weakness. In patients with normal muscle strength mean of finger tapping scores ($m= 44.9 \pm 7.4$) performed by the ipsilesional hand was significantly increased ($p<0.01$) in comparison to finger tapping scores mean being performed by the contralesional one ($m= 38.0 \pm 10.3$) as expected (see figure 6).

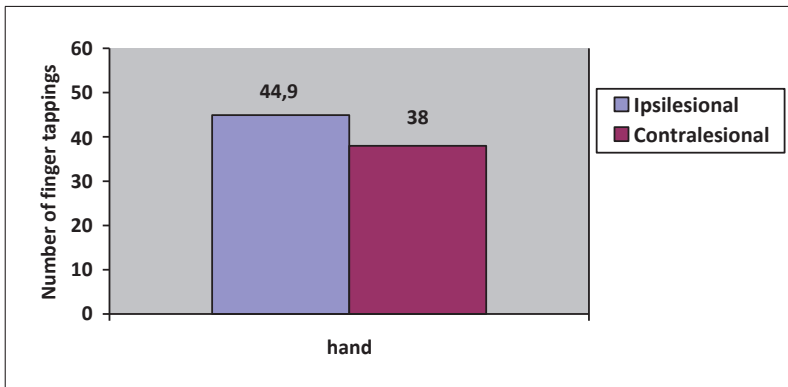


Figure 6. Bar graph showing the mean number of finger tappings of non-paretic patients as performed by ipsilesional and contralesional hands. As expected, finger tapping performance by the hand contralateral to the tumor was reduced when compared to the finger tapping performance by the hand ipsilateral to tumor. The mean difference is significant at the level $p<0.01$.

3.1.2 Language

In regards with language group nine patients showed motor-expressive (Broca's) aphasia while the rest twenty four patients were presented with no paraphasic errors. In overall, phonemic verbal fluency z-scores mean was -0.42 ± 1.3 in patients with no paraphasic errors.

3.2 RS-fMRI data

3.2.1 Patients

In order to rule out confounding factors deriving from demographics and tumor characteristics on the RS-fMRI networks, we investigated gender, age and tumor histology effects on RS-fMRI BOLD-signal. Concerning gender variable we did not observe any significant effect on z-values of networks' BOLD-signal. Specifically, non-statistical significance ($p=.68$) was observed in z-value BOLD-signal intensity between male group (4.1 ± 1.5) and female group (4.65 ± 2.5) for ipsilesional IC7 motor network (see figure 7). Similarly, non-statistical significance ($p=0.88$) was found between male group (7.58 ± 2.3) and female group (7.7 ± 2.8) for contralesional IC7 motor network (see figure 8). In the same line, gender (see figure 9) did not affect significantly z-values of BOLD-signal in language network, although males (4.9 ± 1.4) showed higher RS-fMRI BOLD-signal intensity for IC20 language network than females (3.9 ± 1.9); however, this difference did not reach a statistically significance level ($p=.08$).

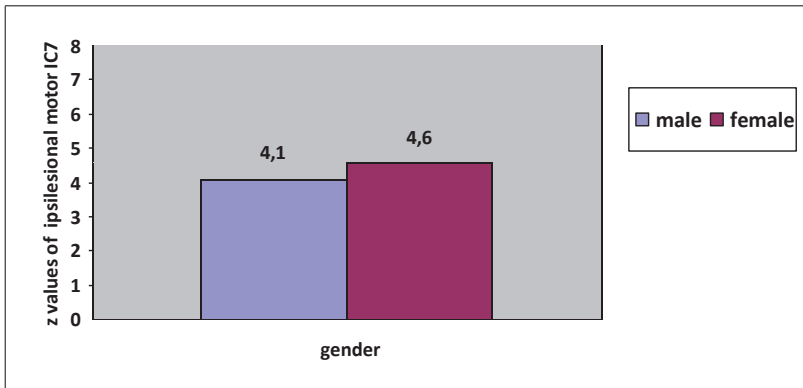


Figure 7. Bar graph showing the mean of z-values of motor IC7 BOLD signal in the ipsilesional pre-central gyrus of males and females in the patients motor group; the mean difference is not statistically significant at the level $p=0.05$.

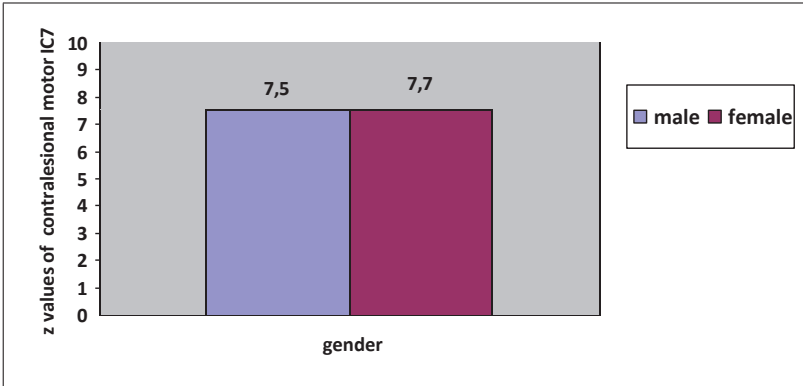


Figure 8. Bar graph showing the mean of z-values of motor IC7 BOLD signal in the contralesional (healthy) pre-central gyrus of males and females in the patients motor group; the mean difference is not statistically significant at the level $p=0.05$.

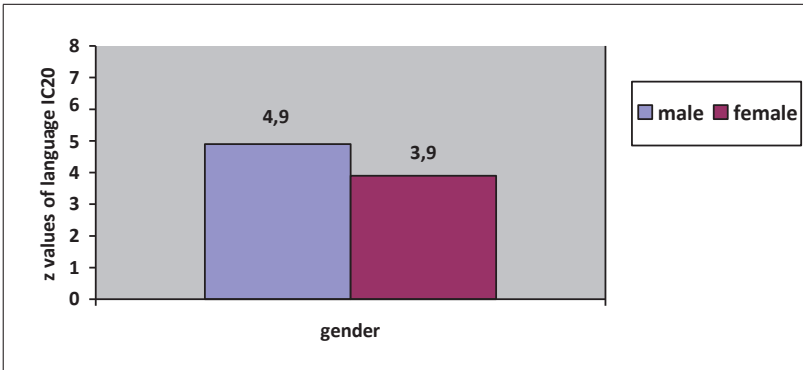


Figure 9. Bar graph showing the mean of z-values of language IC20 BOLD signal in the left frontal inferior gyrus of males and females in the patients language group; the mean difference is not statistically significant at the level $p=0.05$.

In concern with age, we did not find networks' BOLD-signal to be affected by this variable; there was no significant correlation between age and IC7 ipsilesional motor BOLD-signal intensity ($r= 0.01$, $p= 0.91$) neither between age and contralesional one ($r= 0.11$, $p=0.41$). Similar are the results for IC20 language network's BOLD-signal intensity ($r=-0.22$, $p=0.10$). Respective scatter plots are provided in figures 10, 11 &12.

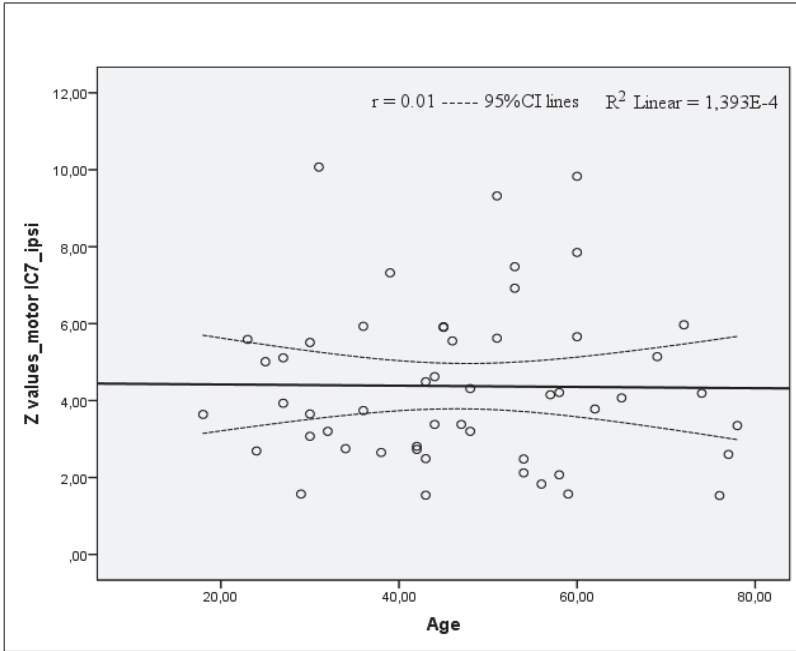


Figure 10. Ipsilesional IC7 pre-central gyrus' RS-fMRI BOLD signal intensity as a function of age in the motor group of patients with tumors in proximity with motor cortex; ipsi=ipsilesional; Age values represent years; Correlation is not significant at the 0.05 level.

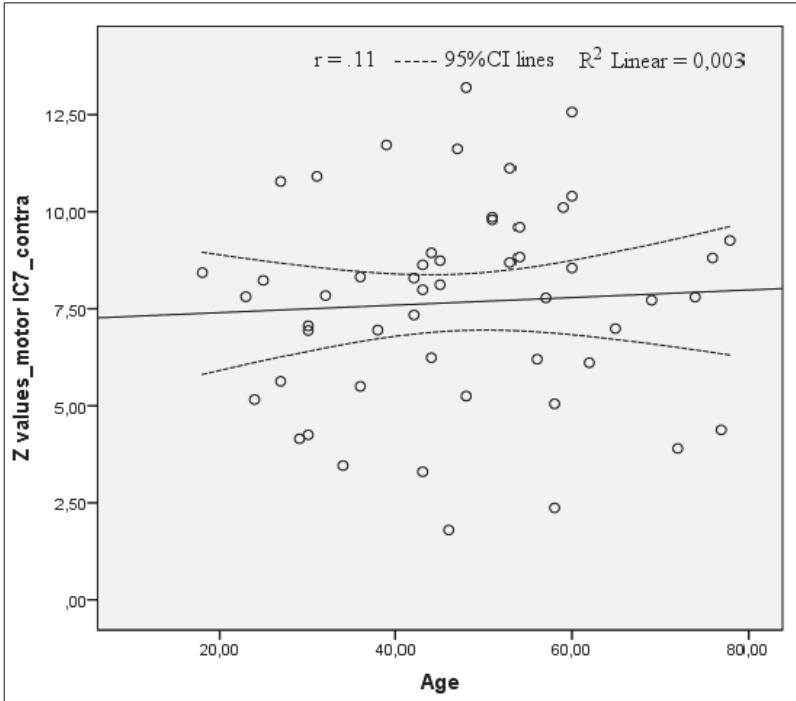


Figure 11. Contralesional (healthy) IC7 pre-central gyrus' RS-fMRI BOLD signal intensity as a function of age in the motor group of patients with tumors in proximity with motor cortex; contra=contralesional; Age values represent years; Correlation is not significant at the 0.05 level.

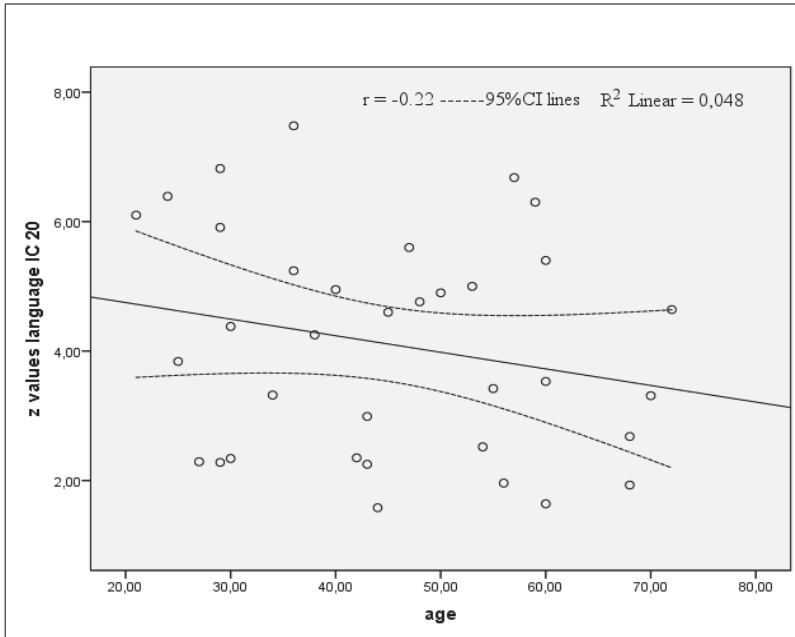


Figure 12. Left IFG (BA 44) RS-fMRI BOLD signal intensity of IC20 as a function of age in the language group of patients harboring tumors near left frontal inferior gyrus; BA= Brodmann area; Age values represent years; Correlation is not significant at the 0.05 level.

Subsequently, we investigated putative effects that the tumor histological profile might have on RS-fMRI networks BOLD-signal. In accordance to our findings, non-statistically significant difference ($p=0.11$) in z-value BOLD-signal intensity was observed when benign-low grade tumor ($n=29$) and high grade tumor ($n=30$) groups were compared in ipsilesional IC7 motor network (see figure 13). In addition, when we divided the clinical motor sample into 3 subgroups (extraparenchymal tumors/meningiomas, low-grade intraparenchymal and high-grade intraparenchymal tumors) there were no statistically significant differences between group means (3.1 ± 1.6 , 4.4 ± 2.0 and 4.8 ± 2.1 respectively) as shown by one-way ANOVA ($F(2, 49) = 2.479$, $p = .094$). Similarly, we did not observe statistically significant difference ($p=0.32$) in BOLD-signal intensity z-values when benign-low grade tumor ($n=23$) and high grade tumor ($n=12$) groups were compared in IC20 language network (see figure

14). Furthermore, when we divided the clinical language sample into 3 subgroups (extraparenchymal tumors/meningiomas, low-grade intraparenchymal and high-grade intraparenchymal tumors) there were no statistically significant differences between group means (3.4 ± 1.7 , 4.1 ± 1.6 and 4.5 ± 1.7 respectively) as shown by one-way ANOVA ($F(2, 32) = 0.860$, $p = 0.43$).

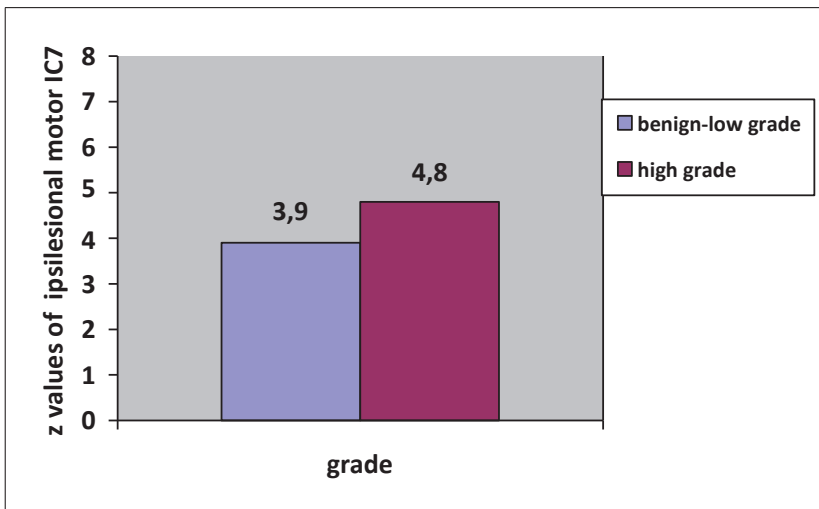


Figure 13. Bar graph showing the mean of z-values of ipsilesional motor IC7 BOLD signal in benign-low grade tumors and high grade tumors groups; the mean difference between groups is not statistically significant at the level $p=0.05$.

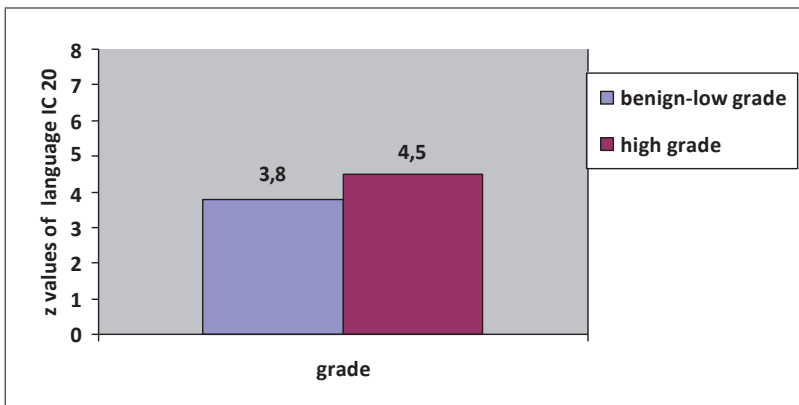


Figure 14. Bar graph showing the mean of z-values of language IC20 BOLD signal in benign-low grade tumors and high grade tumors groups; the mean difference between groups is not statistically significant at the level $p=0.05$.

3.2.2 Healthy subjects

With regards to the healthy subjects results are in the same line with clinical sample's ones. BOLD-signal intensity of RS-fMRI networks was not affected by gender. We did not observe a statistical significance ($p=0.59$) in z-values of BOLD-signal between normal male group (6.9 ± 1.6) and normal female group (7.3 ± 1.5) for left IC7 motor network; we did not observe a statistical significance between normal male group (8.5 ± 1.9) and normal female group (8.3 ± 1.8) for right IC7 motor network ($p=0.84$) either. Gender also did not seem to influence statistically z-values of BOLD-signal intensity in language network as normal males (10.3 ± 1.2) and normal females (8.9 ± 1.1) showed comparable ($p=0.63$) RS-fMRI activations for IC20 language network (see figures 15, 16 & 17 respectively).

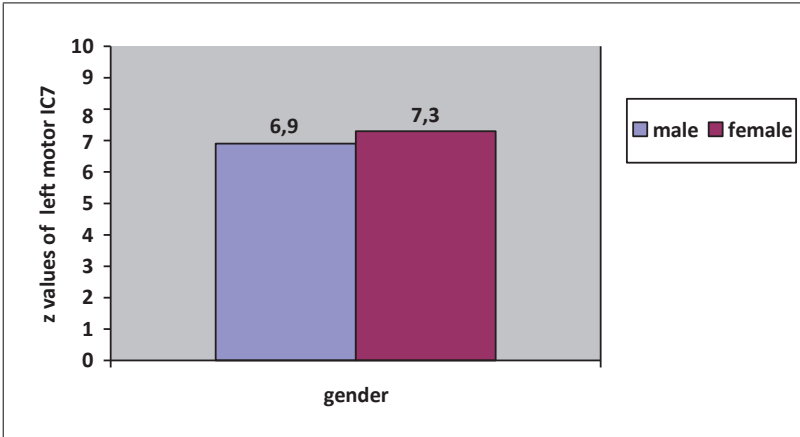


Figure 15. Bar graph showing the mean of z-values of motor IC7 BOLD signal in the left hemisphere pre-central gyrus of males and females in the healthy control group; the mean difference is not statistically significant at the level $p=0.05$.

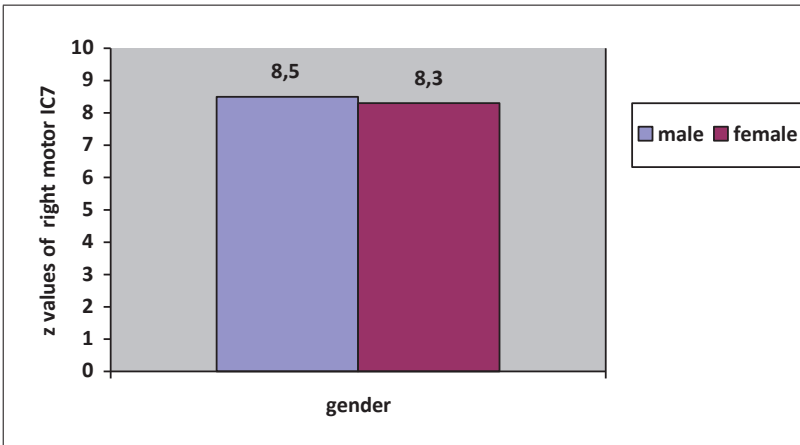


Figure 16. Bar graph showing the mean of z-values of motor IC7 BOLD signal in the right hemisphere pre-central gyrus of males and females in the healthy control group; the mean difference is not statistically significant at the level $p=0.05$.

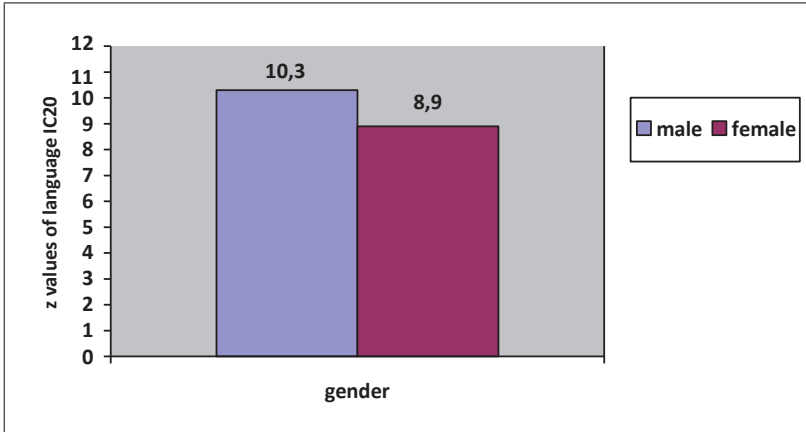


Figure 17. Bar graph showing the mean of z-values of language IC20 BOLD signal in the left frontal inferior gyrus of males and females in the healthy control group; the mean difference is not statistically significant at the level $p=0.05$.

Age also did not show an effect on networks' BOLD-signal intensity; there was no significant correlation between age and IC7 motor BOLD-signal intensity neither in the right hemisphere ($r= -0.17$, $p= 0.39$) nor in the left one ($r= -0.20$, $p=0.29$). Similar are the results for IC20 language RS-fMRI network ($r=0.16$, $p=0.41$). The respective scatter plots are provided in figures 18, 19 & 20.

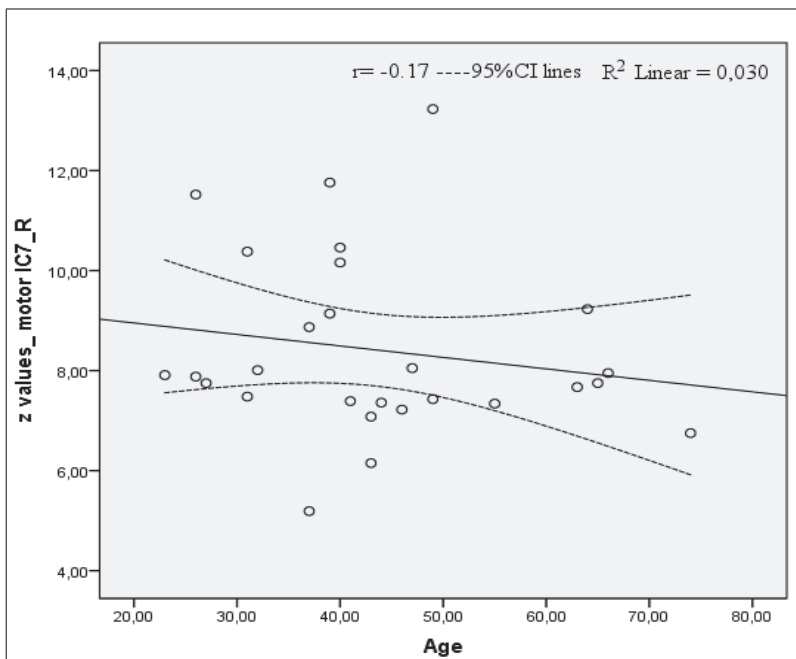


Figure 18. Right hemisphere IC7 pre-central gyrus' activation as a function of age in healthy control group. Age values represent years; Correlation is not significant at the 0.05 level.

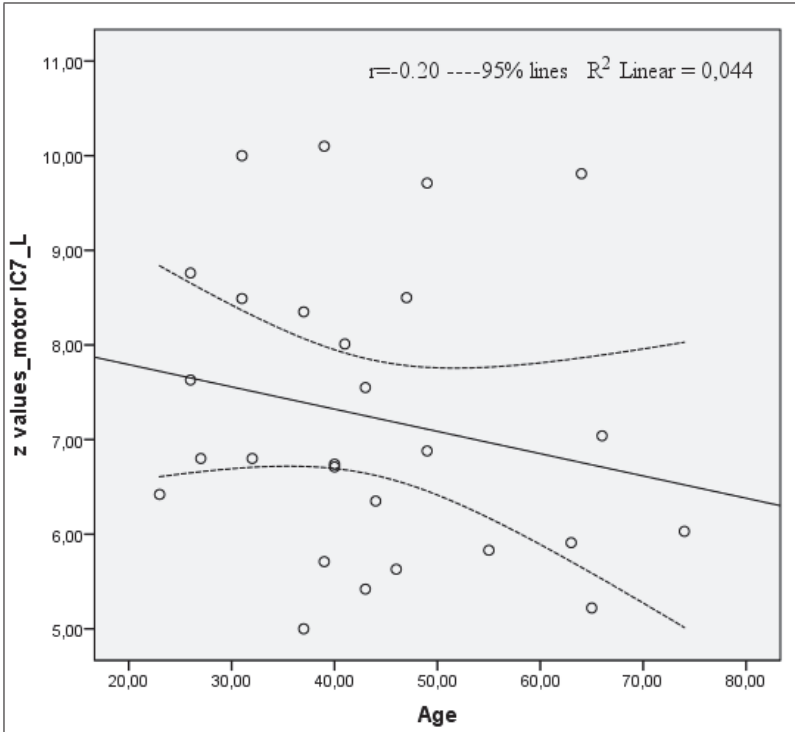


Figure 19. Left hemisphere IC7 pre-central gyrus' activation as a function of age in healthy control group; Age values represent years; Correlation is not significant at the 0.05 level.

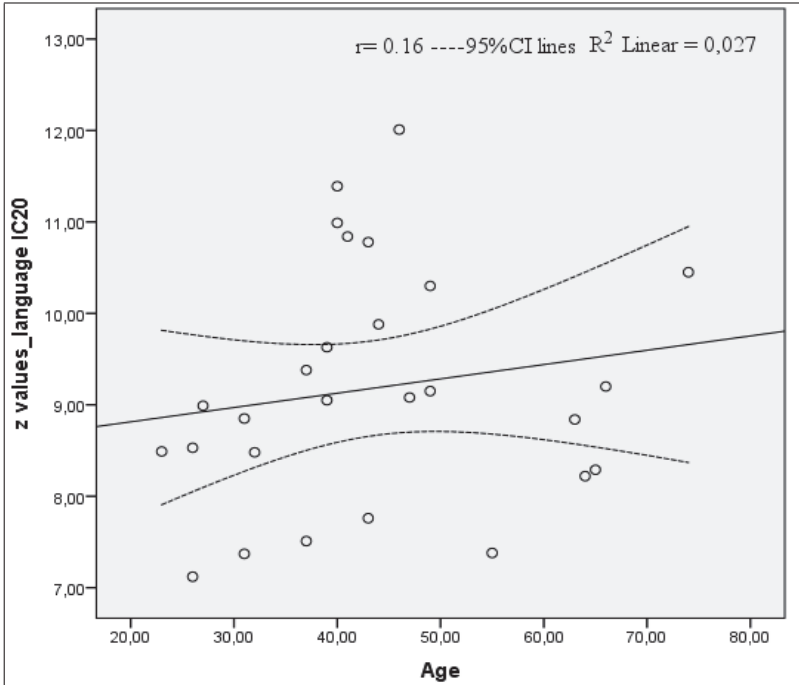


Figure 20. Left IFG (BA44) RS-fMRI BOLD signal intensity of IC20 network as a function of age in the healthy control group; BA= Brodmann area; Age values represent years; Correlation is not significant at the 0.05 level.

3.3 RS-fMRI and clinical data

3.3.1 Motor

There was a strong positive correlation ($r=0.70$, $p<0.01$) between IC7 motor network BOLD-signal z-values and finger tapping performance scores in patients with intact muscle strength (see figure 21).

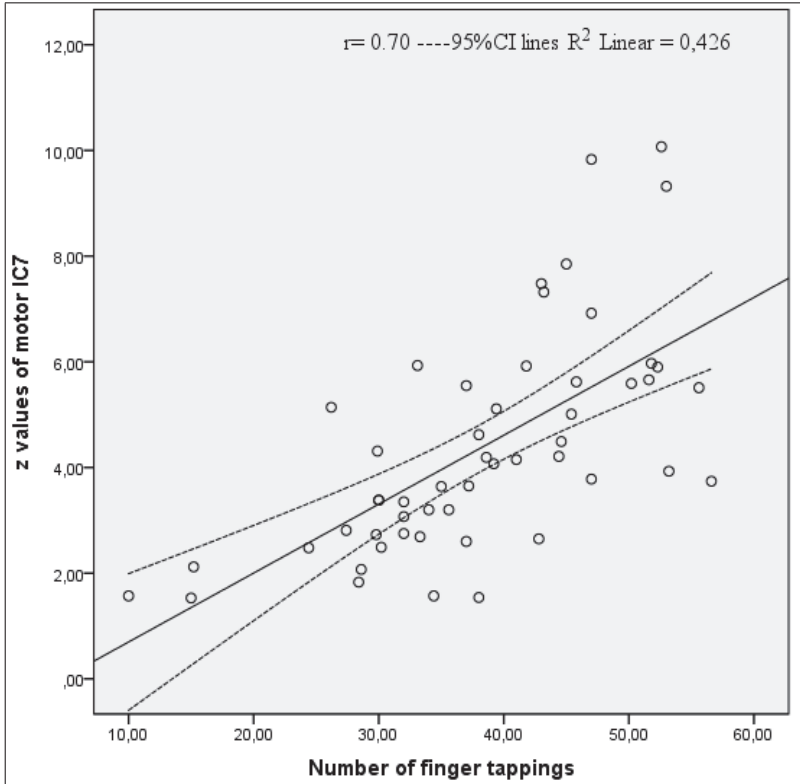


Figure 21. Ipsilesional IC7 (precentral gyrus) BOLD-signal intensity as a function of patients' performance on finger tapping task for the motor group with intact muscle strength; Correlation is significant at the 0.01 level.

In addition, ipsilesional IC7 z-values mean ($m=4.1\pm 2.1$) in the motor group in total showed a statistically significant reduction ($p<0.01$) in comparison to the contralesional z-values mean ($m=7.8\pm 2.5$). Furthermore, ipsilesional IC7 z-scores mean was significantly increased ($p<0.01$) in the motor group with intact muscle strength ($m=4.4\pm 2.0$) in comparison to the respective mean z-scores in the motor group presented with paresis (2.0 ± 0.4). Paradigms of RS-fMRI motor networks in two patients can be seen in Figure 22.

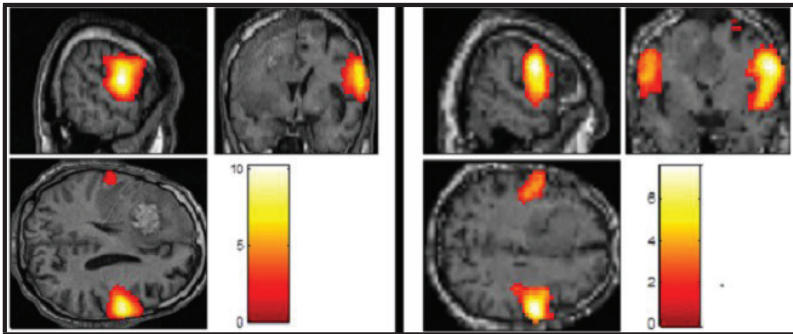


Figure 22. RS-fMRI IC7 motor networks. Left side: IC7 motor network in 3 directions demonstrated in a left frontal HGG patient showing right paresis. Contralesional IC7 BOLD-signal intensity is substantially higher (z- value =10.2) than the ipsilesional IC7 one (z- value =1.66). Right side: IC7 motor network in 3 directions demonstrated in a left frontal meningioma non-paretic patient with, nevertheless, poor finger tapping performance. The contralesional IC7 motor network BOLD-signal intensity (z- value = 4.4) is higher than the ipsilesional one (z- value = 2.6). RS-fMRI images co-registered with structural images; not radiological images (left side = LH, right side=RH); HGG=high grade glioma (Liouta et al., 2018).

3.3.2 Language

Phonemic verbal fluency scores were significantly positively correlated ($r=0.70$, $p<0.01$) with the left IFG (BA44) IC20 BOLD-signal intensity z-scores in the group of patients showing no paraphasias (Figure 23). In addition, left IFG IC20 BOLD-signal

intensity z-scores (2.4 ± 1.0) showed a statistically significant reduction ($p < 0.01$) in the group with aphasia when compared to the respective ones (4.7 ± 1.5) in the group with no aphasia. Due to the fact that IC20 template's peak BOLD-signal is lateralized in the left cerebral hemisphere (Allen et al., 2011) we were not able to investigate possible differences between left and right IFG BOLD-signal intensities. Language network paradigms of two patients can be seen in Figure 24.

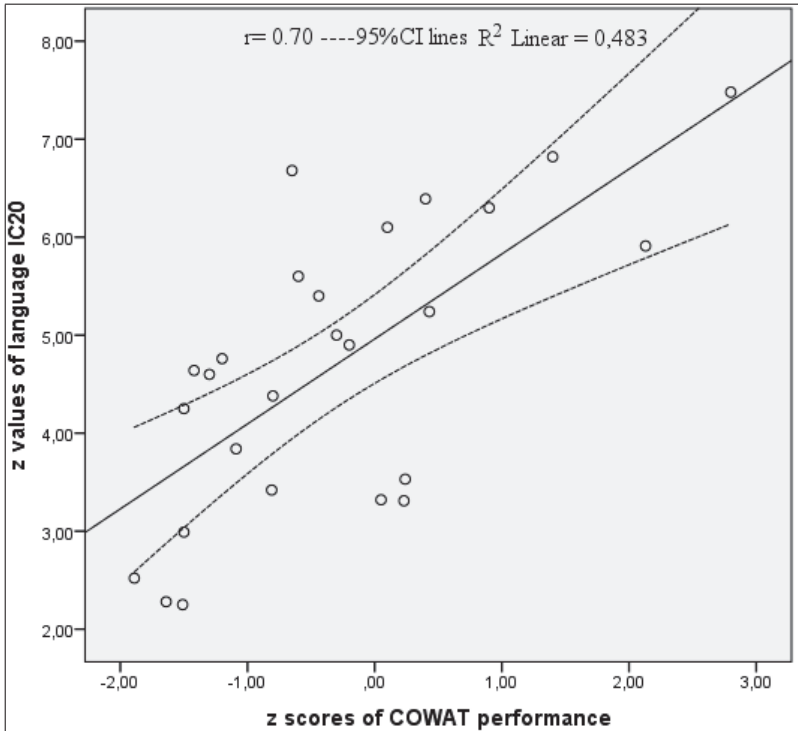


Figure 23. Left IFG (BA 44) BOLD signal intensity as a function of performance on COWAT in patients without aphasic disorder. COWAT z-values represent standardized data. Standard deviations below the normal average (0 value) are indicated by minus values; standard deviations above the normal average are represented by positive values. BA=Brodman Area; COWAT= Controlled Oral Word Association Test. Correlation is significant at the 0.01 level.

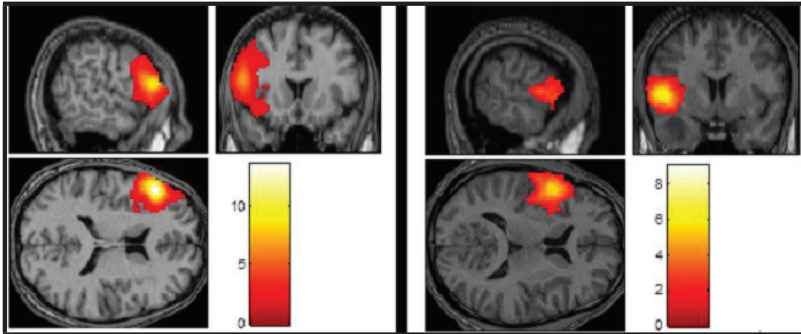


Figure 24. RS-fMRI IC20 language-frontal networks. Left side: IC20 language network in 3 directions demonstrated in a patient harboring a LGG in the left-dominant frontal lobe and with normal phonemic verbal fluency performance. IC20 language network peak z-value-intensity in BA 44 is 6.82. Right side: IC20 language network in 3 directions in a patient with a LGG in the left temporal lobe and with poor phonemic verbal fluency performance. IC20 language network peak z-value intensity in BA 44 is 3.84. RS-fMRI images are co-registered with structural ones; not radiological images (left side=LH/ right side=RH). BA=Brodman area; LGG= low grade glioma (Liouta et al., 2018).

3.4 RS-fMRI in patients and healthy controls: comparison

3.4.1 Motor

Mean of z-values of ipsilesional IC7 BOLD signal in motor patients group ($m=4.09\pm 2.1$) was significantly ($p<0.01$) lower than both the mean of z-values of right hemisphere IC7 BOLD signal ($m=8.41\pm 1.8$) and the mean of z-values of left hemisphere IC7 BOLD signal ($m=7.23\pm 1.5$) in healthy control group (see figures 25 & 26 respectively). In contrast, mean of z-values of contralesional (healthy) IC7 BOLD signal in motor patients group ($m=7.78\pm 2.5$) was not significantly ($p=0.248$) different than the mean of z-values of right hemisphere IC7 BOLD signal ($m=8.41\pm 1.8$) and not

significantly different ($p=0.217$) than the mean of z-values of left hemisphere IC7 BOLD signal ($m=7.23\pm 1.5$) in healthy control group (see figures 27 & 28 respectively).

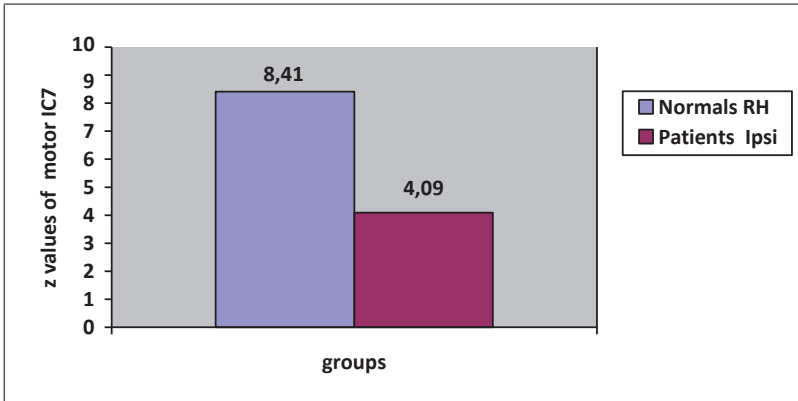


Figure 25. Bar graph showing the mean of z values of motor IC7 BOLD signal in the right hemisphere pre-central gyrus of normal control group and in the ipsilesional pre-central gyrus of patients motor group; RH = right hemisphere; Ipsi=ipsilesional; the mean difference is significant at the level $p=0.01$.

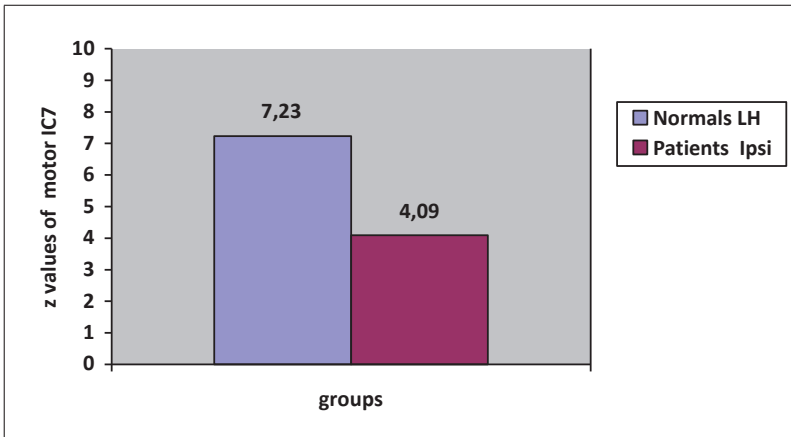


Figure 26. Bar graph showing the mean of z values of motor IC7 BOLD signal in the left hemisphere pre-central gyrus of normal control group and in the ipsilesional pre-

central gyrus of patients motor group; LH = left hemisphere; Ipsi=ipsilesional; the mean difference is significant at the level $p=0.01$.

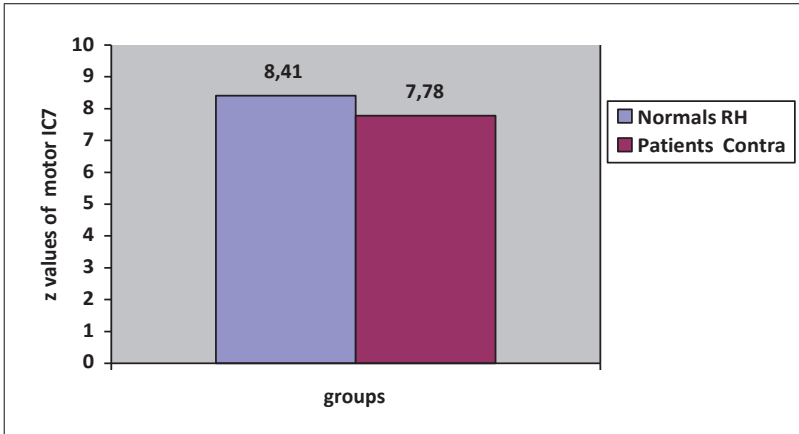


Figure 27. Bar graph showing the mean of z values of motor IC7 BOLD signal in the right hemisphere pre-central gyrus of normal control group and in the contralesional pre-central gyrus of patients motor group; RH = right hemisphere; Contra=contralesional; the mean difference is not significant at the level $p=0.05$.

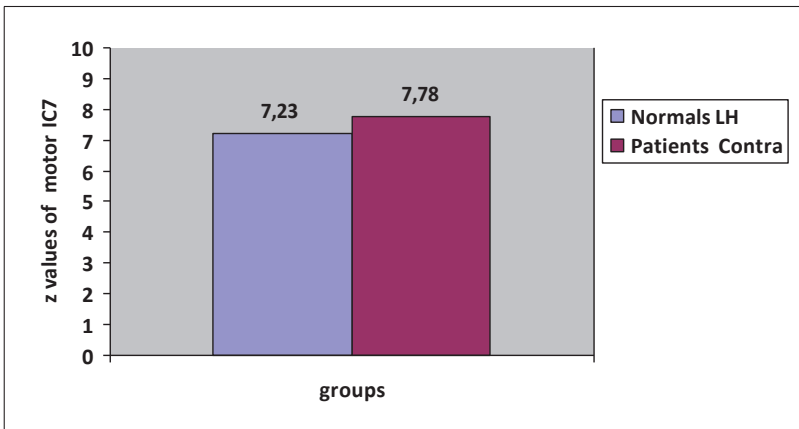


Figure 28. Bar graph showing the mean of z values of motor IC7 BOLD signal in the left hemisphere pre-central gyrus of normal control group and in the contralesional pre-central gyrus of patients motor group; LH = left hemisphere; Contra=contralesional; the mean difference is not significant at the level $p=0.05$.

3.4.2 Language

Mean of z-values of language IC20 BOLD-signal were significantly ($p < 0.01$) reduced in patients with masses near left IFG (figure 29) when the language group ($m = 4.1 \pm 1.6$) was compared to the normal control group ($m = 9.1 \pm 1.3$).

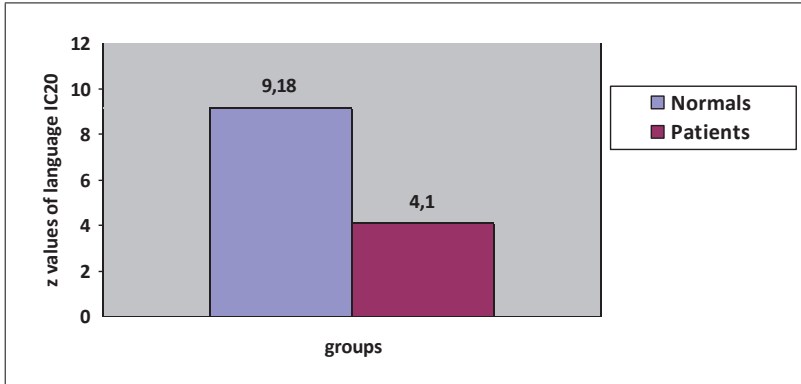


Figure 29. Bar graph showing the mean of z values of motor IC7 BOLD signal in the right hemisphere pre-central gyrus of normal control group and in the ipsilesional pre-central gyrus of patients motor group; RH = right hemisphere; Ipsi=ipsilateral; the mean difference is significant at the level $p = 0.01$.

4. DISCUSSION

4.1 RS-fMRI in brain tumors

Evidence supporting the potential utility of RS-fMRI as a pre-operative tool for functional mapping in brain tumor patients has been derived mainly by studies aiming to compare its spatial-anatomical properties with the ones of the traditional task-based fMRI (Zhang et al, 2009; Liu et al., 2009; Wang et al., 2013; Rosazza et al., 2014; Qiu et al., 2014; Schneider et al., 2016; Sair et al., 2016; Branco et al., 2016). Evidence, however, for its validity by studying preoperatively the RS-fMRI functional relevance in patients with brain masses is relatively scarce. In parallel, since fMRI has no preoperative gold-standard to be compared with, neurocognitive assessment may deliver us important information concerning a brain's area functionality preoperatively. Taken the above into account, aim of this dissertation was to investigate the functional validity of RS-fMRI by associating RS-fMRI motor and language network BOLD-signal intensity with preoperative status of the corresponding neuropsychological functions in patients undergoing brain tumor resection.

4.2 RS-fMRI and motor function

According to our findings RS-fMRI motor network is strongly associated with motor function status. Specifically, patients with paresis exhibited lower RS-fMRI BOLD-signal intensity in primary motor cortex- precentral gyrus ipsilaterally in comparison to the one contralaterally. In addition, ipsilesional RS-fMRI BOLD-signal in the motor cortex-precentral gyrus was reduced in paretic patients in comparison to the one in non-paretic patients. In concern with the group of non-paretic patients, RS-fMRI BOLD intensity on precentral gyrus was strongly correlated with patients' fine motor task performance. The latter extends previous research suggesting that not only intra-axial (Cochereau et al., 2016) but also extra-axial (Liouta et al., 2015) lesions can affect brain function even in cases where no overt deficit can be documented by a typical neurological examination. This indicates that RS-fMRI may be can be used as diagnostic tool even in cases where a typical neurological testing may not document motor disturbances. To the best of our knowledge, the present study is the first one that

supports the validity of preoperative ICA-extracted RS-fMRI motor cortical network through its strong correlation with overt and subtle pre-surgical motor deficits in a considerable sample of brain tumor patients.

As previously mentioned, earlier studies aimed to validate RS-fMRI as a preoperative mapping tool mainly through its comparison with task-based fMRI with the results to be promising. Zhang and colleagues (2009) published one of the first cases series on RS-fMRI and its potential utility in brain tumor pre-surgical planning. In their study they employed four patients with brain tumors affecting the central lobe –the so called sensorimotor cortex. Patients' neuroimaging motor networks were assessed by RS-fMRI and a typical task-based fMRI with patients to perform finger tapping in the latter. According to the authors, the depiction of sensorimotor cortices through RS-fMRI was consistent over multiple scans and RS-fMRI motor mapping yielded similar results with the conventional task-based fMRI (Zhang et al., 2009). During the same year (2009) Liu and colleagues sought as well to investigate the feasibility of RS-fMRI as a presurgical tool for mapping motor function in patients with lesions that were in proximity with pre-central gyrus-the so called motor cortex. Their clinical sample consisted of six patients-candidates for lesion neurosurgical excision and underwent a RS-fMRI by seed-based analysis as well as a traditional task-based fMRI, with upper extremities and tongue movements to be performed by patients in the latter. In support with the previous study, conducted by Zhang and colleagues, authors suggested that motor areas depicted by correlations of low-threshold intrinsic activations were similar to those delineated by the task-based fMRI (Liu et al., 2009). Later studies with relatively larger clinical samples are in line with the previous ones. Qui and colleagues (2014) run both RS-fMRI (with seed-based functional connectivity for hand motor area) and task-based fMRI in 17 patients with gliomas (II-IV grade) near motor cortex. According to the authors both methods were comparable in localizing hand motor area in brain glioma patients (Qui et al., 2014). However, more recent evidence (Hou et al., 2016) suggests that RS-fMRI, as depicted by seed analysis, is not ready yet to be used as a motor mapping tool for pre-surgical planning; comparisons among RS-fMRI and task-based fMRI revealed significant spatial differences (>2cm) in localizing accurately hand motor area.

Concerning ICA method, good spatial correspondence between motor task-based fMRI and motor ICA-derived RS-fMRI has been also suggested. One of the first studies is the one conducted by Kokkonen and colleagues in a series of eight patients with tumors and according to which the localization of sensorimotor cortex with ICA analysis was feasible (Kokkonen et al., 2009). Later literature sought to compare ICA-derived RS-fMRI to conventional fMRI when sub-dividing motor cortex (face, hand and foot cortical areas). Schneider and colleagues (2016) found that sensitivity of RS-fMRI and task-based fMRI were comparable when motor strip was segmented into areas that correspond to different body parts, in a sample of nineteen patients with mixed brain pathologies (gliomas, arteriovenous malformations, metastasis tumors and stroke lesions) (Schneider et al., 2016). Interesting are the results by other studies (Rosazza et al., 2014) supporting that RS-fMRI can indeed localize successfully different areas of the motor brain homunculus, with seed-based analysis, however, to outweigh ICA method in terms of its specificity. Furthermore, the same authors, in line with more recent research (Dierker et al., 2017), noted that RS-fMRI, due to its spatially larger activations, was in partial rather than in complete agreement with task-based fMRI; however researchers concluded that RS-fMRI should be considered as an alternative tool in patients who cannot cooperate and perform successfully a motor task during imaging. In overall, our study provide support for the aforementioned studies by extending their 'RS-fMRI spatial validity' with our 'RS-fMRI functional validity'.

In most of the aforementioned studies, not only spatial properties of task-based fMRI was compared to RS-fMRI but motor (dys)function also was associated with RS-fMRI BOLD-signal intensity; the number of their subjects however was inadequate. In these cases, ECS with electrode grids placement on the sensorimotor cortex during asleep craniotomy was the method the motor dysfunction derived from. However, ECS in asleep craniotomy may only elicit positive symptoms (e.g. unwilling movement-twitching of a body part) but not negative ones (e.g. motor arrest/paresis-apraxia) that is observable clinically through neurological-neuropsychological assessment preoperatively or during awake craniotomy (Schucht et al., 2013). This disadvantage of ECS in asleep patients maybe a possible explanation for the partial agreement between RS-fMRI and ECS sensitivity in identifying motor areas, as reported by some researchers (Dierker et al., 2017). In a more recent study however, ECS has been indeed

conducted in a limited number of awake epilepsy and tumor patients and positive mapping sites were compared with artificial neural network-based RS-fMRI (Mitchel et al., 2013). Authors found their results promising in terms of both methods' functional agreement; it should be noted however that, once again, only positive symptoms were mapped and not negative ones as "motor regions were defined by the presence or absence of induced involuntary motor movements" (Mitchel et al., 2013; page 972, line 25). Until today, the only comprehensive study that has validated the functional relevance of motor resting networks by correlating them with motor areas identified by intraoperative positive and negative (motor arrest, anarthria) symptoms, as elicited by Direct Cortical Stimulation (DCS), is the one by Cochereau and colleagues in 90 glioma patients undergoing awake craniotomy. Researchers claimed that 96% of stimulation sites over sensorimotor strip were placed within 1cm from ICA generated sensorimotor maps, suggesting that ICA maybe be potentially used as a complementary to intraoperative stimulation mapping tool (Cochereau et al., 2016). In general, our study, although used different methodological design, reinforce the results of those studies; in particular, it strengthens the functional validity of RS-fMRI found by these studies in an intraoperative setting with the functional validity of RS-fMRI suggested by our study in a pre-operative setting.

In the same line, evidence of validity of motor cortical RS-fMRI network's functional relevance through correlative studies with preoperative motor neurological-neuropsychological status has been also limited. Otten and colleagues in 2012 sought to investigate how motor functional connectivity, depicted by seed-based approach, is affected in patients with brain tumors that do not lean on primary motor cortex, and whether functional connectivity is correlated with presurgical motor weakness and performance on motor psychometric testing, the grooved pegboard test namely. According to the authors, functional connectivity was diminished in patients with paresis when compared to non-paretic ones; this decrement was especially hold for connectivity between left and right primary motor cortex and between dominant primary motor cortex and non-dominant secondary-premotor area (Otten et al., 2012). Our study, although employed different methodology, provides further support for Otten's study as we also found a decrement in motor networks BOLD-signal in patients with motor weakness in comparison to non-paretic ones. A study by Mallela and

colleagues yielded similar results with motor deficits (muscle weakness) of glioma patients to be associated with loss of functional connectivity between left and right primary motor cortices and SMA only in LGG however and not in HGG (Mallela et al., 2016). Nonetheless, authors do not report the numbers of patients with motor deficits leaving the reader questioning whether results are biased by inadequate clinical sample size.

In concern with fine motor neuropsychological testing in Otten's study, grooved pegboard performance was not correlated with primary motor areas' connectivity but rather with dominant (left) supplementary motor area - premotor area connectivity. Results are quite interesting as they shed light into functional connectivity between motor areas and performance on fine motor function, depicted by neuropsychological testing; however, they do not inform us about the correlation between a standard brain registered-cortical area that elicits functional activation and neuro-psycho-logical function, therefore they may be difficult to be applied in the neurosurgical setting. On the contrary, our correlations between neocortical areas' RSfMRI activations and presurgical status of motor function, support that RS-fMRI may assist in the future neurological surgeons to preoperatively select more sophisticatedly the transcortical approach the surgery should be conducted through.

Overall, the present outcomes support the functional validity of motor ICA-depicted RS-fMRI networks through correlations with gross and subtle motor deficits in patients harboring tumors near central lobe. The present study suggests that RS-fMRI may be utilized in the future in the presurgical setting as a motor function mapping tool, at least in cases where task-based fMRI cannot be conducted due to patients' motor dysfunction, or even in patients under general anesthesia (Bisdas et al., 2016; Roder et al., 2016).

4.3 RS-fMRI and language function

In the present study we investigated the relationship between resting state activity in specific anatomical language areas and patients' pre-surgical clinical status of language function in order to validate RS-fMRI as a potential apparatus in preoperative language mapping. In accordance with our findings RS-fMRI BOLD signal intensity found substantially reduced in aphasic patients in comparison to the respective one in

patients with no aphasia. In the latter group, RS-fMRI BOLD-signal intensity in left IFG (BA44) was observed to be positively correlated with phonemic verbal fluency scoring. Previous studies support that phonemic verbal fluency is a sensitive indicator of frontal lobe dysfunction and suggest that it is strongly functionally supported by BA 44 (Heim et al., 2009; Robinson et al., 2012).

Past studies on language RS-fMRI have been investigated its validity across time, the lateralization of identified networks and the connectivity of different language networks in healthy volunteers. More specifically, research, employing seed based functional connectivity analysis, has been shown the functional asymmetry of the two main language epicentres, the Broca's and the Wernicke's areas namely, with the former area to be left lateralized and the latter right lateralized (Tomasi et al, 2012; Zhu et al, 2014). Language network and its asymmetry have been found reproducible over different lengths of time, providing thus temporal reliability for language resting state network (Zhu et al., 2014). Broca's areas (pars opercularis and pars triangularis) in both hemispheres and their connectivity have been also studied by seed based approach and graph theory, in an attempt to shed light in the role of Broca's homologous area in the right hemisphere of a healthy brain (Muller et al., 2014). Feasibility studies on healthy subjects also have been indicated that ICA extracted language maps could be used in clinical fMRI language mapping in the future of the neurosurgical setting (Tie et al., 2014). Finally, previous research has been suggested that resting state functional connectivity with seeds placed in Broca's epicenter (pars opercularis, pars triangularis and pars orbitalis) can predict the strength of hemispheric lateralization with regards to language function in normals and patients with temporal lobe epilepsy, an information necessary to possess in presurgical planning of pharmaco-resistant temporal epilepsy (Doucet et al., 2015).

In clinical neurological –not brain tumor- setting, only few studies explored RS-fMRI language networks' functional relevance by conducting correlations between resting state functional connectivity and clinical-verbal measures. Pravata and colleagues used a seed based approach (seeds were placed at the pars triangularis according to the verb-generation task fMRI that they had previously conducted) in order to show that, along with the fact that functional connectivity of language network in epilepsy can be atypically lateralized and decreased in left hemisphere epileptic patients (in comparison

to controls), it is also positively correlated with patients' verbal Intelligent Quotient performance (Pravata et al., 2011). Similar are the results provided by stroke studies; Nair and colleagues attempted to investigate the language functional connectivity – verbal fluency performance relationship in a sample of 26 early ischemic stroke patients. According to the authors, patients presented diminished functional connectivity as well as verbal fluency deficits (Nair et al., 2015). Our results are in agreement with the above studies implying that different types of lesions - as epileptic ones in Pravata's study, ischemic ones in Nair's study and space-occupying lesions in our study- can cause a decremental effect on language RS-fMRI and that this reduction can be correlated with verbal deficits not always overt in gross clinical neurological testing.

Regarding brain tumor, research has aimed to validate RS-fMRI by comparison with typical language task-based fMRI; findings indicate that RS-fMRI maybe a valuable tool for language mapping in the preoperative setting. Wang and colleagues investigated language networks, depicted by picture naming task based- BOLD fMRI and group ICA analysis, in forty-three left frontal, left temporal and right hemisphere tumor patients. According to this study, group ICA not only provides a tool for mapping language functional networks but can also give information of how these networks are alternated-reorganized in patients with left hemisphere brain tumors (Wang et al., 2013). A more recent study (Branco et al., 2016) also suggests that RS-fMRI may be a valuable method for mapping language networks pre-surgically; the researchers tested the feasibility of RS-fMRI by comparing traditional verb-to noun generation task based BOLD fMRI and ICA extracted resting state imaging in fifteen patients with brain lesions (the majority of them were intracranial tumors). In general, they found a good overlap between the two methods with resting state's sensitivity and specificity to be the same with that of task-based fMRI and even higher respectively. Similar are the results of Sair and colleagues' study; accordingly, the concordance of task based-fMRI and RS-fMRI analyzed by ICA was modest at a group level (49 brain tumors patients); nonetheless significant variability at the individual level was noted by the authors questioning thus the potential of RS-fMRI to replace or augment task-based fMRI (Sair et al., 2016).

The brain tumor studies mentioned in the last paragraph offer evidence for the spatial-anatomical validity of RS-fMRI; however, they do not offer an insight into the functional validity of RS-fMRI; into the relationship between resting state BOLD-signal

and language function status that can be assessed by clinical- behavioral testing, as we sought in our study. So far, there is limited evidence addressing this topic and this evidence derives from awake tumor craniotomy language cortical mapping data and their relationship with pre-surgical RS-fMRI networks. In 2013, Mitchel and coworkers employed a data-driven approach based on artificial neural network algorithms and analyzed produced resting state language networks and their concordance with intraoperative ECS results (speech arrest) in a small (n=7) number of tumor patients undergoing awake craniotomy. According to their preliminary results their algorithm identified networks in all patients even in those with anamorphic anatomy and the specificity and sensitivity of their resting state method was found high (Mitchel et al., 2013). Later on, Cochereau and colleagues (Cochereau et al.,2016) aimed to elucidate comprehensively the functional validity of resting state connectivity for language networks by comparing connectivity between language seeds and random seeds and by estimating the overlap between ICA resting state networks and results from awake craniotomy mapping in a larger sample (thirty one patients with low grade gliomas). Their results showed that connectivity for language seeds was substantially higher than the random seeds' connectivity and that 92% and 70% of stimulation sites were placed within 1cm and 0.5cm respectively of language ICA generated maps. Authors concluded that a) their results provided a functional validity of resting state networks and b) ICA method succeeded to some extent to differentiate eloquent versus non eloquent areas and thus may be used as a complementary tool in preoperative language mapping. Our findings are in agreement with these studies, strengthening in turn the functional role of the regions included in the resting networks and reinforcing the notion RS-fMRI networks are not correlated merely in an anatomical fashion with typical languages centers.

4.4 RS-fMRI and tumor histology

Since our clinical sample consisted of different tumor grades one would assume that this parameter would have an impact on the signal strength of the depicted networks; therefore we sought to investigate the tumor histology's potential effect on RS-fMRI. In accordance to our findings however, we did not observe any significant difference in RS-fMRI BOLD-signal intensity when extraparenchymal benign, intraparenchymal low

grade and intraparenchymal high grade tumor subgroups compared in motor and language resting state networks.

In the past, a limited number of studies have sought to shed light on the resting state functional alterations that may occur in the setting of different cerebral tumor types. DMN is the network selected by the majority of the literature for analyzing its functional properties across tumors with different histology. Ghumman and colleagues analyzed seed-based DMN connectivity in seventy-three patients who were sub-grouped into intraaxial (glial tumors and metastasis) versus extraaxial (meningiomas) tumor groups and in infiltrative tumors versus non-infiltrating ones groups (Ghumman et al., 2016). Interestingly, group comparisons revealed that DMN connectivity was unrelated to histological type. Although researchers hypothesized that glial tumors, as intra-axial infiltrating lesions they are, would have a more disruptive impact on resting state connectivity than extraaxial tumors such as meningiomas and intraaxial but not infiltrating tumors such as metastases, their findings did not confirm their working hypothesis. However, authors supported that their findings could be due the ‘blind fashion’ of seed placement they employed in their methods, suggesting that future studies should avoid improper, blind to the tumor location, seed placement. Our findings are in agreement with Gumman’s study although different methods of resting analysis were employed and different networks were analyzed by the two studies. Furthermore, our results reinforce Gumman’s findings, as in our study only tumors near the aimed resting networks were included, suggesting that their findings may were not to “the blind fashion” of seed placement as they advocated.

In regards with within glioma analyses, research suggests that HGG in comparison with LGG present a more complicated morphology and resting state fMRI characteristics in the peri-tumoral area (Wu et al., 2015). Accordingly, it is reported that HGG are linked with significantly larger decline in functional connectivity of DMN than the LGG (Harris et al., 2014). In this study resting state fMRI was extracted by task-based fMRI that sixty eight patients with gliomas underwent through. WHO grade was the most significant predictor -among other parameters e.g. patients’ age, tumor volume, Karnofsky Performance Scale - of DMN coherence. Specifically, patients with grade II gliomas showed substantially higher DMN integrity in comparison with grade III and IV glioma patients. Similar are the results of Mallela’s study in which hand motor area’s

resting state connectivity was analyzed in the setting of different glioma grades (Mallela et al., 2016). Twenty-four patients with gliomas participated in this study. In general, HGG showed lower functionality between the motor cortices bilaterally and SMA than LGG. When, however, their clinical sample was sub-divided into patients with motor deficits (defined as muscle strength less than 5/5 from neurological exam) and patients with normal muscle strength, association of functional connectivity decrement with motor deficits was observed only in LLG group and not in HGG one. Authors postulated that decreased RS-fMRI sensitivity in HGG due to neurovascular uncoupling phenomenon (that will be discussed in a later section) may accounts for their observed lack of association between functional connectivity and HGG patients' clinical motor status.

In parallel with seed-based studies, Esposito et al. by recruiting an ICA method, investigated another parameter of resting state connectivity: the laterality of a network, the DMN specifically, in the presence of a left hemisphere glial tumor. In accordance to their results, substantial lateralization of the DMN to the intact hemisphere - the right one- was observed; however, that was hold only for the LGG and not the HGG. Authors suggested a compensatory mechanism that it is known to occur in the LGG due to plasticity (Esposito et al., 2012).

In contrast with the previous studies, Zhang and colleagues did not found significant differences in cerebral resting state connectivity among glioma grades when the entire set of data was analyzed (Zhang et al., 2016). In this study ten LGG and ten HGG patients with frontal tumors of both hemispheres were included and functional connectivity of posterior parietal cortex and temporal-parietal junction was analyzed in order to investigate how DMN is affected by tumors. Correlation analyses did not reveal any significant effect of tumor grade in functional connectivity between the aforementioned seeds for the whole group; nonetheless, when they subdivided the sample according to the tumor lateralization they did found a correlation between left-dominant hemisphere intrahemispheric functional connectivity and tumor grade, with left frontal HGGs to reduce the functional connectivity's strength significantly more than the left frontal LGGs. However, authors argued that studies with larger data sets should be conducted in order to validate their findings. Using a relatively larger sample (39 right- handed patients) however, Briganti et al. claim that patients with left

hemisphere gliomas (46% grade II and 54% grades III & IV) show no significant difference in intra- and inter-hemispheric resting state functional connectivity when they are subdivided into LGG and HGG subgroups (Briganti et al., 2012) and this is in accordance to our study.

In summary, current literature does not seem to provide clear evidence for the association of different tumors grading with different resting state networks' changes. Future studies need to validate our results by using similar methodology (ICA method, large populations and homogeneity of tumors location).

4.5 RS-fMRI in patients and healthy controls: comparison

4.5.1 Motor

In the present study apart from the resting state function of the healthy hemisphere of patients, healthy subjects also served as a control group for the ipsilesional resting state motor function. According to our findings the ipsilesional resting state BOLD-signal, but not the contralesional one, was decreased when compared to the resting state BOLD-signal of healthy participants' motor networks. Our results seem to extend those of the current literature.

In terms of topography previous studies have aimed to analyze the spatial similarity of resting state motor networks between brain tumor patients and healthy participants that served as controls. The first study that explored sensorimotor networks resemblance between tumor patients and healthy controls is the one conducted by Kokkonen and colleagues (Kokkonen et al., 2009). Authors using ICA group analysis in eight patients and ten healthy, suggested a similarity of sensorimotor networks between the two groups and concluded that localization of sensorimotor regions in a brain harboring a tumor can be achieved with ICA method in an analogue way as in a healthy brain. However the small sample size was one of the limitations of this study. More recently, Hou et al. employed a larger clinical sample consisted of twenty-five brain tumor patients and compared quantitatively patients' hand motor areas' spatial properties to the respective of a ten healthy participants' group. Individual as well as group analyses showed that differences in the hand region localization, driven by task-based fMRI, RS-fMRI and anatomical images, were of a much lower scale in healthy subjects in comparison to tumor patients; specifically in none of the healthy participants the

distance among hand motor areas, as evaluated by task-based and RS- fMRI, was larger than 2cm in contrast to patients (Hou et al. 2016).

In terms of functional connectivity strength, previous studies have aimed to investigate potential differences that may exist between patients with neoplasms and healthy controls. In a clinical sample of sixteen patients without motor disturbances Otten et al. report no substantial difference in functional motor network connectivity when compared to the one of a healthy sample (Otten et al. 2012). It should be noted however, that their sample consisted of heterogeneous types of neoplasms and more importantly of variable tumor locations with the majority of them to be located in distant -from classical motor areas- brain regions such as temporal and occipital lobes not affecting thus the primary motor cortices. Since it is known that tumor location is a key parameter having impact on functional connectivity of brain networks (Briganti et al., 2012) one may suspect that the results of this study were influenced by the confounding independent variable of tumor location. A later study sought to control for the above factor by recruiting only patients with LGGs located in proximity with motor areas. Niu et al. aimed to probe motor networks in fifteen patients with no motor symptoms harboring slow growing gliomas in vicinity with central sulcus and compared them with the ones of fifteen age-matched healthy participants. Motor task-based fMRI preceded the resting analysis in order to identify relevant activity in the primary motor cortices and the SMA. In their method researchers employed frequency based analysis by subdividing frequency at three different levels in order to elucidate changes in the power spectral density of low frequency oscillations. Non-parametric testing was employed for between groups average power comparisons and in accordance with their results a) reduced functional connectivity between the left and the right primary motor cortices was found in patients in comparison to the one in healthy controls and b) significantly reducing of power spectral density was observed in all frequency levels (0.01–0.02 Hz; 0.02–0.06 Hz; 0.06–0.1 Hz) in primary motor cortices and SMA for patients compared to controls (Niu et al. 2014).

In summary, the majority of the current literature suggests that resting state motor functionality is altered in patients harboring brain tumors and it is diminished in comparison with healthy individuals. The findings of the present study are in

accordance with previous ones and provide additional relevant evidence in the current literature.

4.5.2 *Language*

In contrast to our motor IC that its main anatomical localization was bilateral (precentral gyri), in our frontal - language IC the main anatomical localization of peak BOLD-signal was lateralized to the left IFG (BA44, 45); therefore contralesional (right) BOLD- signal in the homologous area of Broca could not be used as a control. Thus, we employed the respective IC of healthy participants to serve as a control group. According to our findings language resting network BOLD-signal intensity was significantly reduced in patients harboring masses near left IFG when they were compared to the normal group. Our study seems to reinforce previous clinical studies that appear to support this difference in language resting state functionality between patients with brain lesions and healthy individuals.

In one of those studies (Nairs et al. 2015) the language network's resting state functional connectivity was investigated in a sample of stroke patients (at both early and late-stages); patients had different lesion locations, did not present any significant clinical language deficits and their functional connectivity was compared to the functional connectivity of healthy controls. Authors sought in addition, to elucidate the behavioural correlations of resting state connectivity by testing participants with verbal fluency task, the one used in our study as well. They followed a seed-based approach and using 23 seed ROIs they extracted a broad language network including anatomically inferior and middle frontal gyri, temporo-parietal, basal ganglia and thalamic areas. According to their findings early stroke patients presented significantly reduced resting state functional connectivity in the described language network, compared to healthy controls. Late stage patients on the other hand, did not show the respective difference in network functional connectivity when compared to the one of healthy group. In concern with brain- behavior correlations, their results revealed significant correlations of decreased functional connectivity and deficient performance on verbal fluency test for early stage stroke patients compared with healthy controls (Nair et al., 2015).

Similar findings are provided by Pravata and colleagues in epileptic patients. Researchers aimed to evaluate resting state functional connectivity in twenty-two

patients with pharmaco-resistant epilepsy (lesions were located in left and right frontal and temporal regions) by comparing it with the one in twelve healthy controls. Their language network defined by three regions of pars triangularis bilaterally (6 cortical seeds in total). Authors postulated that left hemisphere patients showed non typical language lateralization, suggesting a functional reorganization, and a decreased connectivity in the language network compared to healthy controls (Pravata et al., 2011).

Evidence for reduced functionally connectivity in language networks is derived also from studies on tumor patients. Briganti et al. sought to explore the rearrangement that a language network's functional connectivity may have in thirty-nine non aphasic patients harboring a left hemisphere glial tumor and to compare their findings to thirteen healthy volunteers. Their language network involved initial ROIs at the pars opercularis of the left IFG and additional ROIs that showed the maximum correlation coefficients with the initial ones. In accordance with authors' results functional connectivity within the language network and mainly in the left temporoparietal junction was significantly lower than the one in normal subjects (Briganti et al., 2012).

In summary lesion studies, involving tumors among other types of cerebral damage, indicate that resting state functionality of language networks is significantly reduced in patients with neighboring lesions compared to normal participants.

4.6 Methodological considerations

As we mentioned in the introduction section several types of RS-fMRI analysis have been developed with ICA and seed-based methods to be the most prominent ones in literature so far. In contrast to ICA, seed-based method demands a pre-selection of ROIs from the researcher; therefore, it might not be the best methodological option for analyzing brain tumor data; it is well known that brain functions maybe relocated in tumors that grow up slowly, due to plasticity mechanism (Duffau et al., 2014), and as such one cannot be confident about the functions that underlie specific structural seeds. Moreover, seed-based method can become especially challenging in cases where language resting state networks are required to be classified, as it is well known that language regions may present great variability in brain tumor patients (Tate et al.,

2014). Taken the above into account, one can assume that ICA rather than seed-based analysis would represent functions- supported by respective anatomical network areas- in a more reliable way in cases that a tumor produce a considerable mass effect (Ghumman et al. 2016).

A second methodological issue in RS-fMRI analysis is the tumor-derived neurovascular uncoupling that may compromise detection of BOLD-signal. HGGs as glioblastomas may occasionally accompanied by false negative BOLD-signal changes in functional imaging. Nonetheless, RS-fMRI and task-based fMRI neurovascular uncoupling is reported in a similar rates (Agarwal et al., 2014); in addition, in our study comparison of HGGs to LGGs groups did not reveal any BOLD-signal difference implying that BOLD-signal in our analysis was not altered by this methodological parameter.

4.7 Conclusions

In the present study, we sought to investigate the validity of ICA produced RS-fMRI as a preoperative functional mapping tool in neurosurgical setting. Therefore, we tested the functional validity of RS-fMRI motor and language networks by investigating their relationship with preoperative clinical neuro-psycho-logical motor and language data in a considerable number of patients harboring a range of brain masses. We demonstrated significant correlational relationships between motor and language RS-fMRI networks' BOLD-signal intensity and underlying clinical motor and language status, preoperatively. We also showed that RS-fMRI networks were significantly affected in patients by their tumor, as compared to healthy-control subjects. Our findings provide support for the functional validity of RS-fMRI and indicate that RS-fMRI may be a valuable preoperative functional mapping tool, considering the restrictions of task-based fMRI. Future research is warranted to explore the relationship between RS-fMRI and postoperative functional status in brain tumor patients.

5. SUMMARY

Background and purpose: Resting state functional magnetic resonance (RS-fMRI) correlation with pre-surgical functional status in patients with brain tumors is scarcely documented in the present literature. Aim of the present study was to investigate the validity of RS-fMRI as potential preoperative functional mapping tool in tumor brain surgery by exploring the association of motor and language RS-fMRI networks with subjects' preoperative performance on motor and language clinical assessment respectively in patients with brain tumor.

Materials and methods: 85 patients presented with brain tumor entities and 27 healthy controls were prospectively recruited for the present study. Clinical sample was subdivided into two groups according to mass localization: patients with tumors in proximity to motor cortex (n=59) underwent clinical examination for gross (paresis-muscle weakness) and fine (finger tapping) motor deficits. Patients harboring tumors in proximity to the left inferior frontal gyrus (n=35) were clinically assessed for apparent (expressive aphasia) and subtle language function (phonological verbal fluency) disturbances. All patients and healthy subjects underwent RS-fMRI with motor and language resting networks being derived by Independent Component Analysis (ICA).

Results: In the motor group, patients with paresis demonstrated significantly ($p < 0.01$) reduced resting state BOLD-signal intensity in ipsilesional motor cortex in comparison to the respective one in contralesional-intact motor cortex. Significantly ($p < 0.01$) decreased BOLD-signal intensity was additionally noticed in ipsilesional motor cortex of patients with paresis in comparison to patients with normal muscle strength. Furthermore, in patients with intact muscle strength, a strong positive correlation ($r = 0.70$, $p < 0.01$) between ipsilesional pre-central gyrus BOLD-signal and performance on finger tapping task was demonstrated. Compared to the healthy group, clinical motor group showed reduced resting state network activity, with patients' ipsilesional pre-central gyrus BOLD-signal intensity to be significantly ($p < 0.01$) lower than normals' left and right pre-central gyri BOLD-signal intensities. Concerning language group, patients presented with expressive aphasia exhibited significantly ($p < 0.01$) reduced RS-fMRI BOLD-signal intensity in left inferior frontal gyrus (Brodmann area 44) when compared with patients without aphasia. In non-aphasic patients, a strong positive correlation ($r = 0.70$, $P < 0.01$) between left inferior frontal gyrus' BOLD-signal intensity

and phonological fluency scoring was demonstrated. Similarly with the motor group, language group also showed significantly ($p < 0.01$) reduced left inferior gyrus RS-fMRI BOLD-signal when compared to healthy controls. Finally, RS-fMRI BOLD signal was not observed to have an association with demographic parameters (age, gender) for both clinical and healthy groups and with tumor histopathological grading for both motor and language clinical groups.

Conclusions: Our findings show a significant affection of motor and language RS-fMRI networks' BOLD-signal intensity by the presence of a tumor and a correlation with clinical performance of patients providing thus evidence for the functional validity of RS-fMRI in brain tumor patients; our results indicate therefore, that RS-fMRI may be a valuable complementary tool for preoperative mapping of eloquent areas, at least in patients who cannot cooperate satisfactory in a traditional task-based motor and language fMRI.

5.1 German Summary

ZUSAMMENFASSUNG

HINTERGRUND UND ZIEL: Die Korrelation der präoperativen funktionellen Magnetresonanztomographie im Ruhezustand (resting-state fMRI, RS-fMRT) mit dem klinischen Status bei Hirntumorpatienten ist bisher in der Literatur nicht adäquat erforscht. Unser Ziel war es, die klinische Relevanz von RS-fMRI zu prüfen, indem wir den Zusammenhang zwischen RS-fMRI Ergebnissen und präoperativer motorischer und sprachlicher Funktion bei Patienten mit Hirntumoren validieren.

MATERIAL UND METHODEN: 85 Patienten mit primären Hirntumoren und 27 gesunde Probanden wurden prospektiv in die Studie eingeschlossen. Patienten mit Tumoren in der Nähe des präzentralen Gyrus ($n = 59$) wurden auf offensichtliche paretische und feine Fingerklopfen (Finger-Tapping) Defizite untersucht. Bei Patienten mit links-frontalen Tumoren in der Nähe des Gyrus frontalis inferior ($n = 35$) wurden die Defizite in Bezug auf die schwere (Aphasie) und milde (phonologische verbale Geläufigkeitsbeeinträchtigung) Sprachstörungssymptome bewertet. Eine RS-fMRT wurde bei allen Teilnehmern durchgeführt und die entsprechenden motorischen und sprachlichen Ruhenetzwerken wurden mittels einer räumlichen Unabhängigkomponentenanalyse (Independent Component Analysis, ICA) generiert.

ERGEBNISSE: Die in der Motorgruppe eingeschlossenen paretischen Patienten zeigten in dem ipsilateralen zur Läsion präzentralen Gyrus signifikant ($p \leq 0,01$) vermindertes BOLD-Signal im Vergleich zu dem kontralateralen gesunden präzentralen Gyrus frontalis. Signifikante Unterschiede ($p < 0,01$) mit reduziertem BOLD-Signal wurden auch in dem ipsilateralen zur Läsion präzentralen Gyrus der motorisch gelähmten im Vergleich zu den nicht paretischen Patienten beobachtet. Bei motorisch asymptomatischen Tumorpatienten wurde eine starke positive Korrelation ($r = 0,70$, $p < 0,01$) zwischen dem BOLD-Signal im ipsilateralen zur Läsion motorischen Kortex und den Finger-Tapping-Testergebnissen gefunden. Im Vergleich mit der Probandengruppe zeigte die Patientengruppe mit Parese eine reduzierte ‚resting-state‘ Aktivität, wobei die Aktivität im ipsilateralen zur Läsion

präzentralen Gyrus signifikant ($p < 0,01$) niedriger als in den Probanden war. Bei den aphasischen Patienten, der linke Gyrus frontalis inferior (Brodmann-Areal 44) wies signifikant ($p \leq 0,01$) erniedrigtes RS-fMRI BOLD-Signal im Vergleich zu den nicht aphasischen Patienten auf. Bei Patienten ohne Sprachstörung wurde eine starke positive Korrelation ($r = 0,70$, $P < 0,01$) zwischen dem BOLD-Signal im linken Gyrus frontalis inferior und den phonologischen Testergebnissen beobachtet. Ähnlich wie bei der motorischen Gruppe, zeigten die Patienten mit Sprachproblemen signifikant ($p = < 0,01$) reduziertes RS-fMRI BOLD Signal im Vergleich zu den gesunden Kontrollen. Das RS-fMRI-BOLD-Signal wies keine Korrelation mit den demographischen Parametern (Alter, Geschlecht) und dem histopathologischen Tumor-Grading sowohl für die Patienten als auch bei den Probanden.

SCHLUSSFOLGERUNGEN: Eine signifikante Beeinträchtigung der motorischen und sprachlichen Netzwerke von Tumorpatienten im Vergleich zu den gesunden Probanden konnte mittels RS-fMRI nachgewiesen werden. Das niedrigere RS-fMRI BOLD Signal in der Nähe der Tumore korrelierte signifikant mit der klinischen neuropsychologischen Leistung der Patienten. Somit stellt sich die RS-fMRI als ein nützliches Instrument zur präoperativen funktionellen Hirnkartierung bei Patienten mit Hirntumoren insbesondere bei Patienten, die bei den herkömmlichen aufgabenbasierten fMRI Paradigmen nicht mitwirken können.

6. BIBLIOGRAPHY

- Agarwal S, Sair HI, Yahyavi-Firouz-Abadi N, Airan R, and Pillai JJ (2014). Neurovascular uncoupling in resting state fMRI demonstrated in patients with primary brain gliomas. *Acta Neurochir (Wien)* 156(12):2295-302. doi: 10.1007/s00701-014-2236-0.
- Allen EA, Erhardt EB, Damaraju E, Gruner W, Segall JM, Silva RF, et al. (2011). A Baseline for the Multivariate Comparison of Resting-State Networks. *Frontiers in Systems Neuroscience* 5:2. doi:10.3389/fnsys.2011.00002.
- Anderson JS, Nielsen JA, Froehlich AL, et al. (2011). Functional connectivity magnetic resonance imaging classification of autism. *Brain* 134:3742–54.
- Beckmann CF, DeLuca M, Devlin JT, et al. (2005). Investigations into resting-state connectivity using independent component analysis. *Philos Trans R Soc Lond B Biol Sci.* 360:1001–13.
- Bisdas S, Charyasz-Leks E, Roder C, Tatagiba MS, Ernemann U, and Klose U (2016). Evidence of Resting-state Activity in Propofol-anesthetized Patients with Intracranial Tumors. *Acad Radiol.* 23(2):192-199.
- Biswal B, Yetkin FZ, Haughton VM, and Hyde JS (1995). Functional connectivity in the motor cortex of resting human brain using echo-planar MRI. *Magn Reson Med* 34(4):537–541
- Bondy M and Ligon BL (1996). Epidemiology and etiology of intracranial meningiomas: A review. *J Neurooncol* 29:197–205.
- Bookheimer S (2007). Pre-surgical language mapping with functional magnetic resonance imaging. *Neuropsychol Rev.* 17:145–155
- Briganti C, Sestieri C, Mattei PA, Esposito R, Galzio RJ, et al. (2012). Reorganization of functional connectivity of the language network in patients with brain gliomas. *AJNR Am J Neuroradiol* 33: 1983–1990.
- Branco P, Seixas D, Deprez S, Kovacs S, Peeters R, Castro SL et al. (2016). Resting-State Functional Magnetic Resonance Imaging for Language Preoperative Planning. *Front. Hum. Neurosci.* 10:11. doi: 10.3389/fnhum.2016.0001132.
- Chen G, Ward BD, Xie C, et al. (2011). Classification of Alzheimer disease, mild cognitive impairment, and normal cognitive status with large-scale network analysis based on resting-state functional MR imaging. *Radiology* 259:213–21.
- Chow DS, Horenstein CI, Canoll P, Lignelli A, Hillman EMC, Filippi CG, and Grinband J (2016). Glioblastoma induces vascular dysregulation in nonenhancing peritumoral regions in humans. *Am. J. Roentgenol.* 206: 1073–1081. doi.org/10.2214/AJR.15.14529.
- Cochereau J, Deverduin J, Herbet G, Charroud C, Boyer A, Moritz-Gasser S, Le Bars E, Bonafé, A, and Duffau H (2016). Comparison between resting state fMRI networks and responsive cortical stimulations in glioma patients. *Hum. Brain Mapp.* 37: 3721–3732. doi.org/10.1371/journal.pone.0059657.

Dierker D, Roland JL, Kamran M, Rutlin J, Hacker CD, Marcus DS, Milchenko M, Miller-Thomas MM, Benzinger TL, Snyder AZ, Leuthardt EC, and Shimony JS (2017). Resting-state Functional Magnetic Resonance Imaging in Presurgical Functional Mapping: Sensorimotor Localization. *Neuroimag Clin N Am* 27: 621–633. doi.org/10.1016/j.nic.2017.06.011

Doucet GE, Pustina D, Skidmore C, Sharan A, Sperling MR, and Tracy JI. (2015). Resting-state functional connectivity predicts the strength of hemispheric lateralization for language processing in temporal lobe epilepsy and normal. *Hum Brain Mapp.* 36(1):288-303.

Duffau H (2014). The huge plastic potential of adult brain and the role of connectomics: New insights provided by serial mappings in glioma surgery. *Cortex* 58:325-337.

Esposito R, Mattei PA, Briganti C, Romani GL, Tartaro A, and Caulo M, 2012. Modifications of default-mode network connectivity in patients with cerebral glioma. *PLoS One* 7: e40231. doi.org/10.1371/journal.pone.0040231.

Fiscaro RA, Jost E, Shaw K, Brennan NP, Peck KK, and Holodny AI (2016). Cortical plasticity in the setting of brain tumors. *Top. Magn. Reson. imaging TMRI* 25: 25–30. doi.org/10.1097/RMR.0000000000000077.

Fox MD, Corbetta M, Snyder AZ, et al. (2006). Spontaneous neuronal activity distinguishes human dorsal and ventral attention systems. *Proc Natl Acad Sci U S A* 103:10046–51.

Fox MD and Raichle ME (2007). Spontaneous fluctuations in brain activity observed with functional magnetic resonance imaging. *Nat Rev Neurosci.* 8:700–711.

Ghinda DC, Wu JS, Duncan NW, and Northoff G (2018). How much is enough—Can resting state fMRI provide a demarcation for neurosurgical resection in glioma? *Neuroscience & Biobehavioral Reviews* 84: 245-261, doi.org/10.1016/j.neubiorev.2017.11.019.

Ghumman S, Fortin D, Noel-Lamy M, Cunnane SC, and Whittingstall K (2016). Exploratory study of the effect of brain tumors on the default mode network. *J. Neurooncol.* 128:437–444. doi.org/10.1007/s11060-016-2129-6.

Giussani C, Roux FE, Ojemann J, Sganzerla EP, Pirillo D, and Papagno C (2010). Is preoperative functional magnetic resonance imaging reliable for language areas mapping in brain tumor surgery? Review of language functional magnetic resonance imaging and direct cortical stimulation correlation studies. *Neurosurgery* 66(1):113-20. doi: 10.1227/01.NEU.0000360392.15450.C9.

Glover GH. (2011). Overview of Functional Magnetic Resonance Imaging. *Neurosurgery Clinics of North America*, 22(2), 133-139. <http://doi.org/10.1016/j.nec.2010.11.001>

- Goodglass H, Kaplan E, and Barresi B (2001). *The Boston diagnostic aphasia examination: BDAE*. Austin, TX: PRO-ED
- Greicius MD, Krasnow B, Reiss AL, and Menon V (2003). Functional connectivity in the resting brain: a network analysis of the default mode hypothesis. *Proc Natl Acad Sci USA* 100(1):253–258. doi:10.1073/pnas.0135058100
- Habets EJJ, Kloet A, Walchenbach R, Vecht CJ, Klein M, and Taphoorn MJ (2014). Tumour and surgery effects on cognitive functioning in high-grade glioma patients. *Acta Neurochir* 156: 1451. doi.org/10.1007/s00701-014-2115-8
- Harris RJ, Bookheimer SY, Cloughesy TF, Kim HJ, Pope WB, Lai A, Nghiemphu PL, Liau LM, and Ellingson BM (2014). Altered functional connectivity of the default mode network in diffuse gliomas measured with pseudo-resting state fMRI. *J. Neurooncol.* 116, 373–379. doi.org/10.1007/s11060-013-1304-2.
- Heim S, Eickhoff SB, and Amunts K (2009). Different roles of cytoarchitectonic BA 44 and BA 45 in phonological and semantic verbal fluency as revealed by dynamic causal modelling. *Neuroimage* 48(3):616–624.
- Hervey-Jumper SL and Berger MS (2014). Role of surgical resection in low- and high-grade gliomas. *Curr Treat Options Neurol.* 16(4):284. doi:10.1007/s11940-014-0284-7.
- Hou BL, Bhatia S, and Carpenter JS (2016). Quantitative comparisons on hand motor functional areas determined by resting state and task BOLD fMRI and anatomical MRI for pre-surgical planning of patients with brain tumors. *NeuroImage : Clinical.* 11:378-387. doi:10.1016/j.nicl.2016.03.003
- Jovčevska I, Kočevar N, and Komel R. (2013). Glioma and glioblastoma - how much do we (not) know? (Review). *Molecular and Clinical Oncology* 1(6):935-941. <https://doi.org/10.3892/mco.2013.172>
- Klein M, Duffau H, and De Witt Hamer PC. (2012). Cognition and resective surgery for diffuse infiltrative glioma: an overview. *Journal of Neuro-Oncology* 108(2): 309–318. <http://doi.org/10.1007/s11060-012-0811-x>
- Koch W, Teipel S, Mueller S, et al. (2012). Diagnostic power of default mode network resting state fMRI in the detection of Alzheimer's disease. *Neurobiol Aging.* 33:466–78.
- Kokkonen SM, Nikkinen J, Remes J, Kantola J, Starck T, Haapea M, Tuominen J, Tervonen O, and Kiviniemi V (2009). Preoperative localization of the sensorimotor area using independent component analysis of resting-state fMRI. *Magn. Reson. Imaging* 27, 733–740. doi.org/10.1016/j.mri.2008.11.002.
- Kosmidis MH, Vlahou CH, Panagiotaki P, and Kiosseoglou G. (2004). The verbal fluency task in the Greek population: normative data, and clustering and switching strategies. *J Int Neuropsychol Soc.* 10:164-172.
- Lang S, Duncan N, and Northoff G (2014). Resting-State Functional Magnetic Resonance Imaging: Review of Neurosurgical Applications. *Neurosurgery* 74 (5): 453-465. doi: 10.1227/NEU.0000000000000307.

- Lee MH, Smyser CD, and Shimony JS (2013). Resting state fMRI: A review of methods and clinical applications. *AJNR Am J Neuroradiol.* 34(10):1866–1872. doi:10.3174/ajnr.A3263.
- Liouta E, Katsaros V.K, Stranjalis G, Leks E, Klose U, Bisdas S. (2018). Motor and language deficits correlate with resting state functional magnetic resonance imaging networks in patients with brain tumors. *Journal of Neuroradiology, in press*, <https://doi.org/10.1016/j.neurad.2018.08.002>.
- Liouta E, Koutsarnakis C, Liakos F. et al. (2015). Effects of intracranial meningioma location, size, and surgery on neurocognitive functions: a 3-year prospective study. *Journal of Neurosurgery* 124(6): 1578-1584. DOI: 10.3171/2015.6.JNS1549
- Liu H, Buckner RL, Talukdar T, Tanaka N, Madsen JR, and Stufflebeam S (2009). Task-free presurgical mapping using functional magnetic resonance imaging intrinsic activity. *J Neurosurg.* 111:746–754.
- Louis DN, Perry A, Reifenberger G et al. (2016). The 2016 World Health Organization Classification of Tumors of the Central Nervous System: a summary. *Acta Neuropathol* 131: 803. doi.org/10.1007/s00401-016-1545-1
- Mallela AN, Peck KK, Petrovich-Brennan NM, Zhang Z, Lou W, and Holodny AI, (2016). Altered resting-State functional connectivity in the hand motor network in glioma patients. *Brain Connect.* 6, 587–595. doi.org/10.1089/brain.2016.
- Marko NF, Weil RJ, Schroeder JL, Lang FF, Suki D, and Sawaya RE. (2014). Extent of resection of glioblastoma revisited: personalized survival modeling facilitates more accurate survival prediction and supports a maximum-safe-resection approach to surgery. *J Clin Oncol.* 32(8):774–82. doi:10.1200/jco.2013.51.8886.
- Mitchell TJ, Hacker CD, Breshears JD, Szrama NP, Sharma M, Bundy DT, ... Leuthardt EC (2013). A Novel Data-Driven Approach to Preoperative Mapping of Functional Cortex Using Resting-State Functional Magnetic Resonance Imaging. *Neurosurgery*, 73(6), 969–983. <http://doi.org/10.1227/NEU.0000000000000141>
- Muller AM and Meyer M (2014). Language in the brain at rest: new insights from resting state data and graph theoretical analysis. *Front Hum Neurosci.* 8: 228.
- Nair VA, Young BM, La C, Reiter P, Nadkarni TN, Song J et al. (2015). Functional connectivity changes in the language network during stroke recovery. *Annals of Clinical and Translational Neurology* 2(2):185–195.
- Niu C, Zhang M, Min Z, Rana N, and Zhang Q (2014). Correction: motor network plasticity and low-frequency oscillations abnormalities in patients with brain gliomas: a functional MRI study. *PLoS One* 9 (5), e96850. doi.org/10.1371/journal.pone.0096850.
- Otten ML, Mikell CB, Youngerman BE, Liston C, Sisti MB, Bruce JN, et al. (2012). Motor deficits correlate with resting state motor network connectivity in patients with brain tumors. *Brain* 135:1017–1026.

- Qiu TM, Yan CG, Tang WJ, Wu JS, Zhuang DX, Yao CJ, et al. (2014). Localizing hand motor area using resting-state fMRI: validated with direct cortical stimulation. *Acta Neurochir.* 156:2295–2302. DOI 10.1007/s00701-014-2236-0
- Pignatti F, van den Bent M, Curran D, et al. (2002). Prognostic factors for survival in adult patients with cerebral low-grade glioma. *J Clin Oncol* 20:2076–2084.
- Posner J, Park C, and Wang Z (2014). Connecting the dots: A review of resting connectivity MRI studies in Attention-Deficit/Hyperactivity Disorder. *Neuropsychol Rev.* 24(1): 3–15. doi:10.1007/s11065-014-9251-z.
- Pravatà E, Sestieri C, Mantini D, Briganti C, Colicchio G, and Marra C (2011). Functional Connectivity MR Imaging of the Language Network in Patients with Drug-Resistant Epilepsy. *AJNR Am J Neuroradiol.* 32:532– 540.
- Prigatano GP and Hoffmann B (1997). Finger Tapping and Brain Dysfunction: A Qualitative and Quantitative Study. *Barrow Quarterly* 13(4).
- Reitan RM and Wolfson D (1985). *The Halstead-Reitan neuropsychological test battery*. Tucson: Neuropsychology Press
- Robinson G, Shallice T, Bozzali M, and Cipolotti L (2012). The differing roles of the frontal cortex in fluency tests. *Brain* 135:2202–2214.
- Roder C, Charyasz-Leks E, Breitkopf M, Decker K, Ernemann U, Klose U, et al. (2016). Resting-state functional MRI in an intraoperative MRI setting: proof of feasibility and correlation to clinical outcome of patients. *J Neurosurg.* 1:1-9.
- Rosazza C, Aquino D, D’Incerti L, Cordella R, Andronache A, and Zacà D. (2014). Preoperative Mapping of the Sensorimotor Cortex: Comparative Assessment of Task-Based and Resting-State fMRI. *PLoS ONE* 9(6):e98860.
- Sair HI, Yahyavi-Firouz-Abadi N, Calhoun VD, Airan RD, Agarwal S, Intrapromkul J, Choe AS, Gujar SK, Caffo B, Lindquist MA and Pillai JJ (2016). Presurgical brain mapping of the language network in patients with brain tumors using resting-state fMRI: Comparison with task fMRI. *Hum. Brain Mapp.* 37: 913–923. doi:10.1002/hbm.23075
- Saraf S, McCarthy BJ, and Villano JL. (2011). Update on Meningiomas. *The Oncologist* 16(11): 1604–1613. doi.org/10.1634/theoncologist.2011-0193
- Schneider FC, Pailler M, Faillenot I, Vassal F, Guyotat J, Barral FG, et al. Presurgical Assessment of the Sensorimotor Cortex Using Resting-State fMRI (2016). *AJNR Am J Neuroradiol.* 37(1):101-107. Doi:10.3174/ajnr.A4472
- Schucht P, Moritz-Gasser S, Herbet G, Raabe A, and Duffau H (2013). Subcortical electrostimulation to identify network subserving motor control. *Hum Brain Mapp.* 34(11):3023-30.
- Supekar K, Menon V, Rubin D, et al (2008). Network analysis of intrinsic functional brain connectivity in Alzheimer’s disease. *PLoS Comput Biol.* 4:e1000100.

- Takamura T. and Hanakawa T. (2017). Clinical utility of resting-state functional connectivity magnetic resonance imaging for mood and cognitive disorders. *J Neural Transm* 124:821–839. DOI 10.1007/s00702-017-1710-2
- Tate MC, Herbet G, Moritz-Gasser S, Tate JE, and Duffau H. (2014). Probabilistic map of critical functional regions of the human cerebral cortex: Broca's area revisited. *Brain* 137(Pt 10):2773-2782.
- Tie Y, Rigolo L, Norton IH, Huang R.Y, Wu W, Orringer D, Mukundan Jr. S, and Golby AJ. (2014). Defining Language Networks From Resting-State fMRI for Surgical Planning—A Feasibility Study. *Hum Brain Mapp.* 35(3): 1018–1030. doi:10.1002/hbm.22231.
- Tomasi D, Volkow ND. (2012). Resting functional connectivity of language networks: characterization and reproducibility. *Mol Psychiatry* 17(8):841-854. DOI: [10.1038/mp.2011.177](https://doi.org/10.1038/mp.2011.177)
- Tuovinen N, de Pasquale F, Caulo M, Caravasso CF, Giudice E, Miceli R, Ingrosso G, Laprie A, Santoni R, Sabatini U (2016). Transient effects of tumor location on the functional architecture at rest in glioblastoma patients: three longitudinal case studies. *Radiat. Oncol.* 11: 107. doi.org/10.1186/s13014-016-0683-x.
- Vanhau denhuysse A, Noirhomme Q, Tshibanda LJ, et al. (2010). Default network connectivity reflects the level of consciousness in non-communicative brain-damaged patients. *Brain* 133:161–71.
- Vassal M, Charroud C, Deverduin J, Le Bars E, Molino F, Bonnetblanc F, Boyer A, Dutta A, Herbet G, Moritz-Gasser S, Bonafé A, Duffau H, and de Champfleury NM (2017). Recovery of functional connectivity of the sensorimotor network after surgery for diffuse low-grade gliomas involving the supplementary motor area. *J. Neurosurg.* 126 :1181–1190. doi.org/10.3171/2016.4.JNS152484
- Wang L, Chen D, Yang X, Olson JJ, Gopinath K, Fan T. et al. (2013). Group Independent Component Analysis and Functional MRI Examination of Changes in Language Areas Associated with Brain Tumors at Different Locations. *PLOS ONE* 8(3): e59657. doi.org/10.1371/journal.pone.0059657.
- Wu J, Qian Z, Tao L, Yin J, Ding S, Zhang Y, and Yu Z (2015). Resting state fMRI feature-based cerebral glioma grading by support vector machine. *Int. J. Comput. Assist. Radiol. Surg.* 10:1167–1174. doi.org/10.1007/s11548-014-1111-z.
- Yu Q, Allen EA, Sui J, Arbabshirani MR, Pearlson G, and Calhoun VD (2012). Brain connectivity networks in schizophrenia underlying resting state functional magnetic resonance imaging. *Curr Top Med Chem.*12(21): 2415–2425.
- Zhang D, Johnston JM, Fox MD, Leuthardt EC, Grubb RL, Chicoine MR, et al. (2009). Preoperative Sensorimotor Mapping in Brain Tumor Patients using Spontaneous Fluctuations in Neuronal Activity Imaged with fMRI: Initial Experience. *Neurosurgery* 65(6): 226–236.

Zhang H, Shi Y, Yao C, Tang W, Yao D, Zhang C, Wang M, Wu J, and Song Z (2016). Alteration of the intra- and cross- hemisphere posterior default mode network in frontal lobe glioma patients. *Sci. Rep.* 6: 26972. doi.org/10.1038/srep26972.

Zhu L, Fan Y, Zou Q, Wang J, Gao JH, and Niu Z (2014). Temporal Reliability and Lateralization of the Resting-State Language Network. *PLOS ONE* 9(1):e85880.

7. DECLARATION OF CONTRIBUTIONS

Concept of the study: Professor Sotirios Bisdas, Dr. Vasileios Katsaros, Evangelia Liouta, MSc.

Design of the study: Professor Sotirios Bisdas, Evangelia Liouta Msc.,

Carrying out the experiments: Liouta Evangelia, MSc.

Professor Uwe Klose and Edyta Charyasz-Leks provided technical support in resting state analysis.


Carrying out the statistical analysis: Liouta Evangelia Msc.

Providing data: Dr Vasileios Katsaros provided the MRI original sequences for post processing resting state analysis. Professor George Stranjalis provided the clinical sample i.e patients with brain tumors. Evangelia Liouta conducted all pre- and post-processing resting state analyses of MRI sequences and clinical neurological/neuropsychological examination of patients.

Gathering of Data: Liouta Evangelia Msc.

Supervision of work: Professor Sotirios Bisdas

Doctoral candidate's name: Evangelia Liouta

Doctoral candidate's signature.....

Date: 09/10/2018

8. PUBLICATIONS

Liouta E, Katsaros V.K, Stranjalis G, Leks E, Klose U, Bisdas S. (2018). Motor and language deficits correlate with resting state functional magnetic resonance imaging networks in patients with brain tumors. *Journal of Neuroradiology*, *in press*, <https://doi.org/10.1016/j.neurad.2018.08.002>.

9. ACKNOWLEDGEMENTS

I would like to sincerely thank Professor of Neuroradiology Dr. Sotirios Bisdas for providing me with constant support and encouragement throughout the present work. It has been a real honor for me to be supervised by such a talented and a worldwide-recognized scientist.

I also thank Dr. Vasileios Katsaros for his valuable contribution into this thesis by providing the MRI sequences. Without his great interesting into neurosciences, this work would be difficult to be conducted.

In addition, I thank Professor of Neurosurgery George Stranjalis for providing us with the clinical sample of the present dissertation. Without his great contribution the present thesis would be impossible to have been written.

Furthermore, I thank Professor Uwe Klose and Edyta Charyasz-Leks, Msc, for their valuable technical support with regards to the resting state analysis.

Finally, I deeply thank all the brain tumor patients that took part in the present study.

Curriculum vitae

Education	<p>2014- present Medical School, University of Tübingen, Germany. Dr.Sc.Hum. candidate</p> <p>2004 -2005 University of Bristol, Bristol, UK MSc Neuropsychology</p> <p>2001-2004 University of Greenwich, London, UK BSc (Hons) Psychology; grade: 2.1</p>
Work experience	<p>2006-2007 Neurofeedback Center, Athens, Greece Clinical Assistant in Neurofeedback sessions</p> <p>2007-present Athens Medical School, Neurosurgery Department, Evangelismos Hospital, Athens, Greece. Clinical and Research Neuropsychology Associate</p>
Academic experience	<p>2009-2011 University of Hertfordshire, UK / IST College, Department of Psychology, Athens, Greece Teaching staff in BSc Psychology undergraduate program. Courses: 1) Biopsychology I & II, 2) Cognitive Neuropsychology 3) Advanced Topics in Memory.</p> <p>2012-present National Kapodistrian University of Athens, Medical School, Athens, Greece Teaching staff in MSc Clinical Neuropsychology postgraduate programme. Courses: 1) Neuropsychological Consequences of Brain Tumors 2) Traumatic Brain Injury</p>
Awards	19th European Conference of Society for Stereotactic and Functional Neurosurgery (ESSFN), 2010, Athens. Best Research Protocol with title "Transcranial Alternating Current Stimulation (tACS) effects on Cognitive Event-Related (ERPs) in patients with Persistent Vegetative State (PVS) or

	Minimally Conscious State (MCS)".
Publications	<ol style="list-style-type: none"> 1. Evangelia Liouta, George Stranjalis, Aristotelis V. Kalyvas, Christos Koutsarnakis , Stavroula Pantinaki , Faidon Liakos, Spyros Komaitis, Lampis C. Stavrinou. Parietal association deficits in patients harboring parietal lobe gliomas: A prospective study. <i>Journal of Neurosurgery</i>. https://thejns.org/doi/abs/10.3171/2017.12.JNS171799 [Epub ahead of print] 2. Liouta E, Gatzonis S, Kalamatianos T, Kalyvas A, Koutsarnakis C, Liakos F, Anagnostopoulos C, Komaitis S, Giakoumettis D, Stranjalis G. Finger tapping and verbal fluency post-tap test improvement in INPH: its value in differential diagnosis and shunt-treatment outcomes prognosis <i>Acta Neurochir (Wien)</i>. 2017; 159(12):2301-2307. doi: 10.1007/s00701-017-3301-2. 3. Koutsarnakis C, Liakos F, Kalyvas AV, Skandalakis GP, Komaitis S, Christidi F, Karavasilis E, Liouta E, Stranjalis G. The Superior Frontal Transsulcal Approach to the Anterior Ventricular System: Exploring the Sulcal and Subcortical Anatomy Using Anatomic Dissections and Diffusion Tensor Imaging Tractography. <i>World Neurosurg</i>. 2017; 106:339-354. doi: 10.1016/j.wneu.2017.06.161 4. Koutsarnakis C, Liakos F, Kalyvas AV, Liouta E, Emelifeonwu J, Kalamatianos T, Sakas DE, Johnson E, Stranjalis G: Approaching the Atrium through the Intraparietal Sulcus: Mapping the sulcal morphology and correlating the surgical corridor to underlying fiber tracts. <i>Oper Neurosurg (Hagerstown)</i>. 2017 ;13(4):503-516. doi: 10.1093/ons/opw037. 5. Ulyte A, Katsaros VK, Liouta E, Stranjalis G, Boskos C, Papanikolaou N, Usinskiene J, Bisdas S. Prognostic value of preoperative dynamic contrast-enhanced MRI perfusion parameters for high-grade glioma patients. <i>Neuroradiology</i>. 2016;58(12):1197-1208. 6. Aristotelis V. Kalyvas, Evangelia Liouta, Spyros Komaitis,

	<p>Christos Anagnostopoulos, George Stranjalis. Idiopathic Intracranial Hypertension: Epidemiology, Pathophysiology, Clinical Features and Contemporary Management. <i>Hospital chronicles</i> 2016, 11(2): 1–8.</p> <p>7. Evangelia Liouta, Christos Koutsarnakis, Faidon Liakos, George Stranjalis. Effects of intracranial meningioma location, size, and surgery on neurocognitive functions: a 3-year prospective study. <i>Journal of Neurosurgery</i> 12/2015; DOI:10.3171/2015.6</p> <p>8. Christos Koutsarnakis, Faidon Liakos, Evangelia Liouta, Konstantinos Themistoklis, Damianos Sakas, George Stranjalis. The cerebral isthmus: fiber tract anatomy, functional significance, and surgical considerations. <i>Journal of Neurosurgery</i> 09/2015; DOI:10.3171/2015.3.</p> <p>9. Evangelia Liouta, Theodosios Kalamatianos, Faidon Liakos, George Stranjalis. Neuropsychological examination detects post-operative complications in idiopathic normal pressure hydrocephalus (iNPH): report of two cases. <i>Neurocase</i> 02/2014; 21(2). DOI:10.1080/13554794.2014.890726</p> <p>10. Liouta Evangelia, Liakos Faidon, Koutsarnakis Christos, Katsaros Vasileios, Stranjalis George. A novel case of familial Normal Pressure Hydrocephalus (NPH). <i>Psychiatry and Clinical Neurosciences</i> 02/2014; 68(7). DOI:10.1111/pcn.12176</p> <p>11. Stranjalis George, Korfias Stefanos, Liouta Evangelia. Contemporary management of intracranial tumors. <i>Hospital Chronicles</i> 76, Supplement 1 987-999, 2014.</p> <p>12. Efthymios Angelakis, Evangelia Liouta, Nikos Andreadis, Stephanos Korfias, Periklis Ktonas, George Stranjalis, Damianos E Sakas. Transcranial Direct Current Stimulation Effects in Disorders of Consciousness. <i>Archives of physical medicine and rehabilitation</i> 09/2013; 95(2).</p> <p>13. E Angelakis, E Liouta, N Andreadis, A Leonardos, P Ktonas, L C</p>
--	---

	<p>Stavrinou, P C Miranda, A Mekonnen, D E Sakas. Transcranial alternating current stimulation reduces symptoms in intractable idiopathic cervical dystonia: A case study. <i>Neuroscience Letters</i> 11/2012; 533(1). DOI:10.1016/j.neulet.2012.11.007</p> <p>14. Efthymios Angelakis, Evangelia Liouta. Transcranial Electrical Stimulation: Methodology and Applications. <i>Journal of Neurotherapy</i> 10/2011; 15(4):337-357. DOI:10.1080/10874208.2011.623092</p> <p>15. Efthymios Angelakis, Nikos Andreadis, Evangelia Liouta, Theofanis Flaskas, Dimitris Verganelakis, Damianos Sakas. Consciousness in non-responsive patients: fMRI and EEG data. <i>Neuroscience Letters</i> 07/2011; 500. DOI:10.1016/j.neulet.2011.05.175</p> <p>16. Efthymios Angelakis, Eleftheria Dede, Evangelia Liouta, Panayiotis Patrikelis, Theophanis Flaskas, Stylianos Gatzonis, Damianos Sakas . Detecting higher cortical function in patients with pervasive vegetative or minimally conscious state with qEEG coherence. <i>Annals of General Psychiatry</i> 01/2008; 7(Suppl 1). DOI:10.1186/1744-859X-7-S1-S359</p> <p>17. Evangelia Liouta, Alastair D Smith, Christine Mohr. Schizotypy and pseudoneglect: A critical update on theories of hemispheric asymmetries. <i>Cognitive Neuropsychiatry</i> 04/2008; 13(2):112-34. DOI:10.1080/13546800801936698</p>
--	--